

1940

# Accessory Adrenal Cortical Bodies in the Pig

James W. Gilmore  
*Iowa State College*

Follow this and additional works at: [http://lib.dr.iastate.edu/iowastate\\_veterinarian](http://lib.dr.iastate.edu/iowastate_veterinarian)



Part of the [Veterinary Anatomy Commons](#)

---

## Recommended Citation

Gilmore, James W. (1940) "Accessory Adrenal Cortical Bodies in the Pig," *Iowa State University Veterinarian*: Vol. 2 : Iss. 2 , Article 15.  
Available at: [http://lib.dr.iastate.edu/iowastate\\_veterinarian/vol2/iss2/15](http://lib.dr.iastate.edu/iowastate_veterinarian/vol2/iss2/15)

This Article is brought to you for free and open access by the Student Publications at Iowa State University Digital Repository. It has been accepted for inclusion in Iowa State University Veterinarian by an authorized editor of Iowa State University Digital Repository. For more information, please contact [digirep@iastate.edu](mailto:digirep@iastate.edu).

# Accessory Adrenal Cortical Bodies in the Pig

JAMES W. GILMORE\*  
Class of 1941

IT IS A WELL known fact that laboratory animals not injected with adrenal cortical extracts may survive the removal of both adrenal glands because of accessory adrenal cortical tissue (1) which is usually located in close approx-

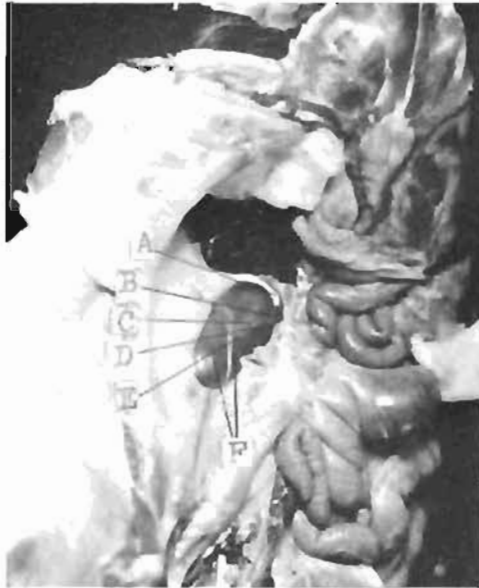

Figure 1

The gross specimen showing the right kidney's ventral surface with the accessory adrenal cortical bodies. A, the medial portion of the right adrenal gland; B, C, D, and E, are the accessory bodies located on the kidney F.

imation to the kidneys. Without either the cortex of the adrenal glands or the possible presence of accessory adrenal cortical tissue, the animals such as the rat, the rabbit, and the guinea pig cannot live unless adrenal cortical extract is administered. Whether or not this is true of a domestic animal, as the pig, re-

\*The author wishes to thank Dr. L. H. Schwarte of the Veterinary Research Institute for the photographs.

mains for researchers to tell us; but if adrenalectomy is ever to be attempted in the pig, the possibility of the presence of accessory adrenal cortical tissue should not be overlooked.

Figure one is a gross picture of a dissected pig which demonstrates the location of some very minute tissues suspected of being accessory adrenal bodies at the time of autopsy because of their location and color.

The nature of these tissues has been determined by stripping the peritoneum from the surface of the kidney (Figure one) (F) extending from the accessory gland (E) to (B). Since the accessory glands were removed along with the kid-

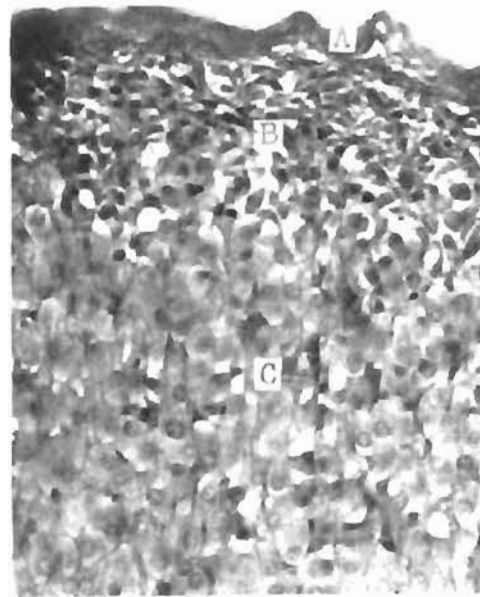


Figure 2

A photomicrograph of an accessory adrenal cortical body. A, the capsule; B, an outer cortical zone; C, an inner cortical zone.  
H&E x500

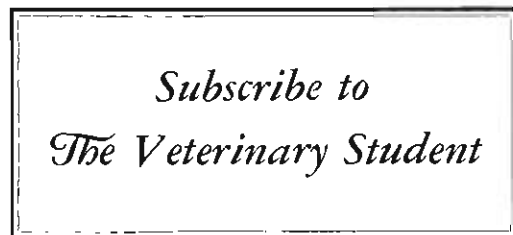ney's peritoneum, it has been possible to serially section the entire region so as to include the accessory glands (E), (D), (C), and (B) also shown in Figure one. It must be noticed, however, that the adrenal gland (A) (Figure one) is located along the anterior border of the right kidney and not as is usually found in the pig according to Sisson (2) who states, "each adrenal lies along the medial border of the corresponding kidney from the hilus forward."

The photomicrograph (Figure two) shows the typical histological structure of one of the accessory adrenal bodies. The capsule (A) and also the zones of the cortex (B) and (C) are easily distinguished. Although the accessory adrenal did not compare identically with the adrenal (A) (Figure one) which was used as a control tissue in that it possessed more vascularity and larger cellular size, the accessory cortical bodies correspond histologically in every other way. The zones (Figure two) (B) and (C) resemble the glomerulosa and the fasciculata respectively of the normal adrenal. (Figure one) (A).

The six distinct and separate accessory adrenal cortical bodies were composed entirely of an outer capsule and a cortex. The cortex seemingly possessed a typical outer zone, the glomerulosa, and another zone corresponding to the fasciculata. No part of these bodies resembled the reticularis of the normal glands, and also no medullary tissue was found in any of these accessory adrenal cortical bodies.

#### Bibliography

- (1) Starling, E. H., Human Physiology. 1936, pages: 984-986.  
 (2) Sisson, S., Anatomy of Domestic Animals, Edition No. 3, page: 569.



## Christmas Party

The annual Christmas party was held on Tuesday, December 12. This year the program was held in McKay Auditorium; the first time it had not been held in the Veterinary Auditorium. However, the ever increasing attendance makes it imperative that the larger facilities be used in the future.

The program for the evening was as follows:

- Group singing ..... led by C. H. Covault  
     "God Bless America"  
     "Joy to the World"
- Piano selections ....J. Bradley Crundwell
- Male Quartette .....R. Helvig, M. Jones, R. Derrer and R. Kufrin  
     "Winter Song"  
     "Silent Night"
- Tap Dance .....Charlene Mae Smith  
     "Box and Cox"—One-Act Play  
     Directed by Margaret W. Sloss
- John Box, A Printer ..... Darrell Cotter
- James Cox, A Hatter ..Howard W. Dunne
- Mrs. Bouncer, Landlady ....Arthur Orum
- Scene: A room in a rooming house.
- Vocal Selections .....C. H. Covault  
     "The House by the Side of the Road"  
     "In Old Judea"
- Wormology .....Frank W. Failing,  
     William Knoop, M. Beemer  
     "Prelude in B Sharp"
- Group singing .....Led by C. H. Covault  
     "Jingle Bells"
- Master of Ceremonies ....H. F. Beardmore

After the program, a lunch was served in the foyer of the Auditorium.

Especial thanks are due to Lois Meyer, Margaret Sloss, John Arnold, Ray Read, and the Committee headed by Merthyn Miner for their fine cooperation and assistance in aiding in the planning and development of the program.

A clever frontispiece for the printed programs was produced by Roy E. Kyner.

Much favorable comment was heard relative to the type of program held and the removal to the larger Auditorium.