

1950

A Case of Dystocia Due to Hydrops Amnii Associated with a Fetal Monster.

D. H. Crawford
Iowa State College

Follow this and additional works at: http://lib.dr.iastate.edu/iowastate_veterinarian



Part of the [Large or Food Animal and Equine Medicine Commons](#), and the [Veterinary Pathology and Pathobiology Commons](#)

Recommended Citation

Crawford, D. H. (1950) "A Case of Dystocia Due to Hydrops Amnii Associated with a Fetal Monster.," *Iowa State University Veterinarian*: Vol. 12 : Iss. 1 , Article 10.

Available at: http://lib.dr.iastate.edu/iowastate_veterinarian/vol12/iss1/10

This Article is brought to you for free and open access by the Student Publications at Iowa State University Digital Repository. It has been accepted for inclusion in Iowa State University Veterinarian by an authorized editor of Iowa State University Digital Repository. For more information, please contact digirep@iastate.edu.

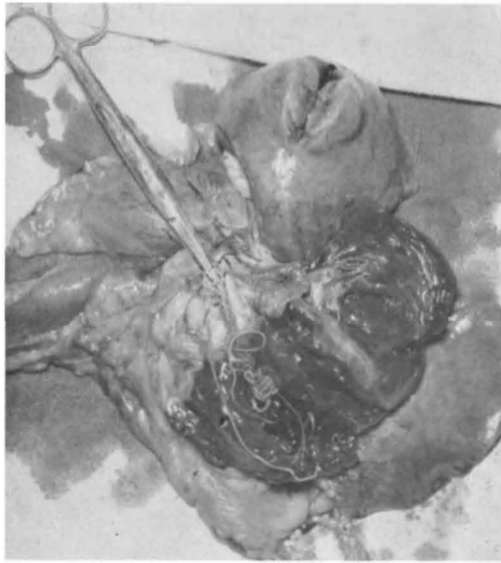


Fig. 2. Heart opened to show adult worms.

this information the owner granted permission to perform euthanasia which was accomplished by the administration of a lethal dose of pentobarbital sodium.

Autopsy revealed a heart which grossly showed very little enlargement, but the right ventricle was dilated, flaccid and definitely atonic. Adult heart worms measuring up to 20 cm. in length were found in the lumen of the right ventricle. Several were in the pulmonary artery partially occluding that vessel. Infarcts and foci of necrosis in the lungs were found indicating parasitic emboli. Other lesions noted were fibrosis of the liver, chronic catarrhal enteritis and a neoplastic-like growth 3 cm. in diameter in the right diaphragmatic lobe of the lungs.

Canine filariasis has been diagnosed in every section of the country, but is more prevalent in the South. Upon checking the history of this case it was found that she was born in New York, went from there to Pennsylvania and finally came to Iowa. It is likely that she picked up the dirofilaria in the East as the disease is more common there. Also, it is approximately a year after the initial infection by the heart worm until the mature dirofilaria are found in the heart.

Verle Footz, '51

4

A Case of Dystocia Due to Hydrops Amnii Associated with a Fetal Monster.

A 6-year-old grade Holstein dairy cow was referred to Stange Memorial Clinic because of dystocia. The cow was due to freshen and labor was noticed first some four hours before the patient was brought to the clinic. History revealed that for the past two months the cow's abdomen was becoming excessively large, but it was assumed by the owner that the cow was going to have twins.

On examination the patient appeared bright and in good condition, the abdomen was distended somewhat more than normal, the vulva was enlarged, and the cow occasionally strained moderately.

Examination per vaginam showed the cervix well dilated, and at full arm's length the top of a firm object could be touched with the finger tips. The same object could be felt by low abdominal ballottement. The fetal membranes were distended with fluid and it was with some difficulty that a finger was forced through the membranes and the opening enlarged by tearing. Many gallons of fluid gushed forth and the cow began to strain more frequently, each expulsive effort causing a gallon or so of fluid to gush out. After some of the fluid had escaped it was possible to reach down into the uterus and grasp a fetal leg and bring it up toward the pelvic inlet. One could feel a withered leg, a small tail and several fairly sharp bony projections in the pelvic region. No clear-cut normal relationship of parts could be established. A diagnosis of dystocia due to hydrops amnii associated with a fetal monster, probably *Schistosomus reflexus*, was made.

Embryotomy was contemplated but a caesarean section was decided upon for the following reasons:

1. The fetus was relatively small, but due to the deformities, rather extensive embryotomy would be required, and in general, caesarean section is to be preferred because it is postive.
2. As the prognosis for the life of the

cow was considered to be unfavorable due to the hydrops amnii, regardless of the method used to overcome the dystocia, caesarean section would afford the opportunity to study the intact fetus.

The operation was performed in the right paralumbar fossa, standing position, using local anesthetic of 4 percent procaine hydrochloride solution. Several abnormally large blood vessels were encountered while incising the muscles which required immediate ligation. The upper part of the posterior abdominal cavity was empty, indicating that the cow had eaten but little for some time. The gravid right horn was easily pulled up to the flank and incised. Despite the small size of the fetus, a relatively large incision was necessary in order to pull the monster out. The placenta was removed very easily due to necrotic cotyledons. The fetal haircoat was covered with meconium.

The uterus was closed with two rows of suture using the Cushing stitch, peritoneum and muscles each with one row of continuous sutures; all sutures of No. 4 chromic catgut. Interrupted mattress sutures of umbilical tape closed the skin incision, with bottom drainage insured.

For prophylaxis the cow was given sulfanilamide powder, 1 gr. per pound, per os, for four days. To encourage rumen motility and for stimulation the following was given via stomach tube:

Five gal. hot water containing 16 Gm. Tartar Emetic, 4 Gm. F.E. Nux Vomica, 5 oz. F.E. Ginger, 1 oz. F.E. Gentian, and 1 ox. Aromatic Spirits of Ammonia.

Surprisingly, the patient made a rather uneventful recovery, and at no time did she appear particularly depressed. Milk production increased steadily up to about 40 pounds daily a few days after the operation. The skin sutures were removed on the tenth day and the case discharged

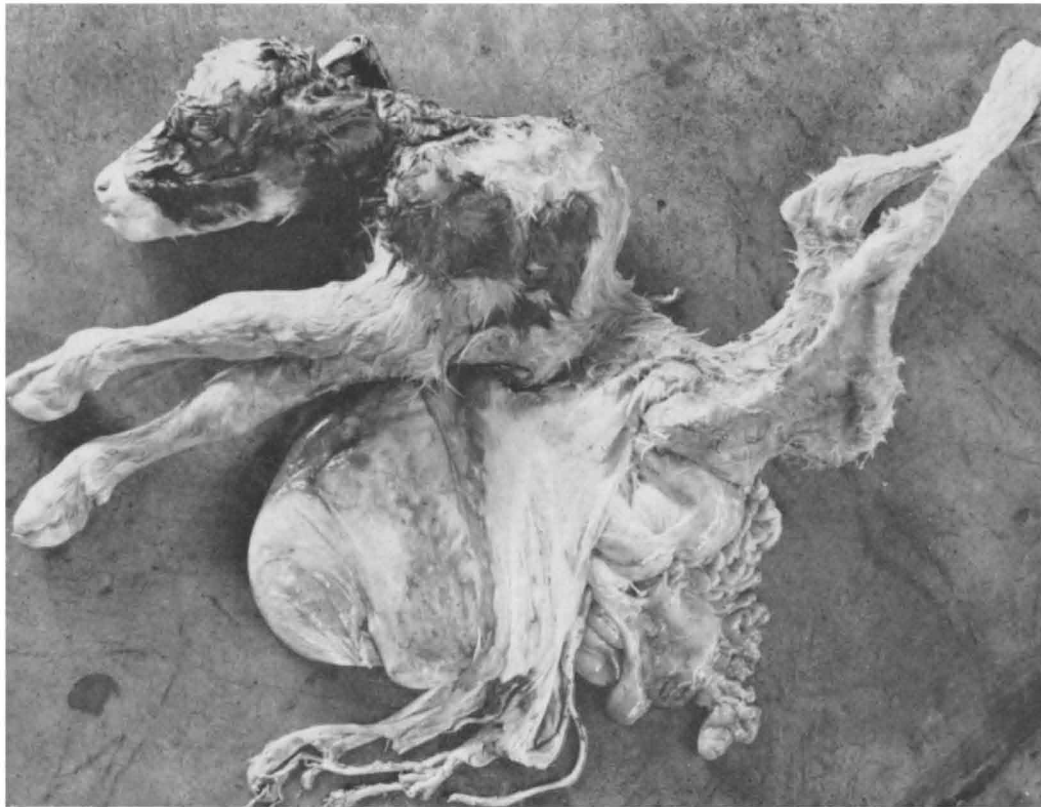


Fig. 3. The fetal monster after removal

on the eleventh post-operative day.

The owner was advised to milk the cow until production dropped to an uneconomic level and then sell her for slaughter.

It is not clear whether the fetal monster should be classified as a *Schistosomus reflexus* or as a *Perosomus elumbis*, as it showed characteristics common to both types of anomaly. As shown by the photograph (fig. 1) the abdominal viscera lay free outside of the normal limits of the body wall due to failure of the somatopleure to grow down and fuse on the ventral abdominal midline. The thoracic viscera were normally enclosed within a deformed chest cavity. Development was arrested in the midthoracic region so that there was complete absence of posterior thoracic, lumbar, sacral and coccygeal vertebrae. The incomplete pelvis with rear legs attached was rotated 180° about its transverse axis to allow the rear legs to extend dorsally, and the underdeveloped tail to be located near the skull, the whole attached to the anterior part of the body by skin only.

Grossly all of the abdominal and thoracic viscera were identified and normal relations were established for the organs. The rumen was distended to about the same size as the abomasum (abomasum normal in size). The right kidney was underdeveloped and located far back in the abdominal region. There was no anus and the rectum ended blindly in the anal region.

D. H. Crawford, '50

5

Fibroma Removal by Cautery.

A 2-year-old American Saddle stallion was admitted to Stange Memorial Clinic on June 15, 1949, with a growth protruding laterally from the pastern region on the right front foot. According to the owner, the neoplasm had been growing slowly for several months. The owner wished the patient castrated in addition to removal of the neoplasm.

On June 16, 1949, the horse was placed in the stocks and given 45 Gm. of chloral hydrate via stomach tube. He was then

restrained on the operating table in a left recumbent position. A classical castration was performed.

Preparatory to removal of the growth, the area around it was shaved and painted with 7 percent tincture of iodine. The area surrounding the lateral digital nerve of the right front leg was infiltrated with 2 percent procaine hydrochloride solution. When anesthesia was complete the tumor was removed by means of the Nicholson firing iron. By this method, more complete control of hemorrhage

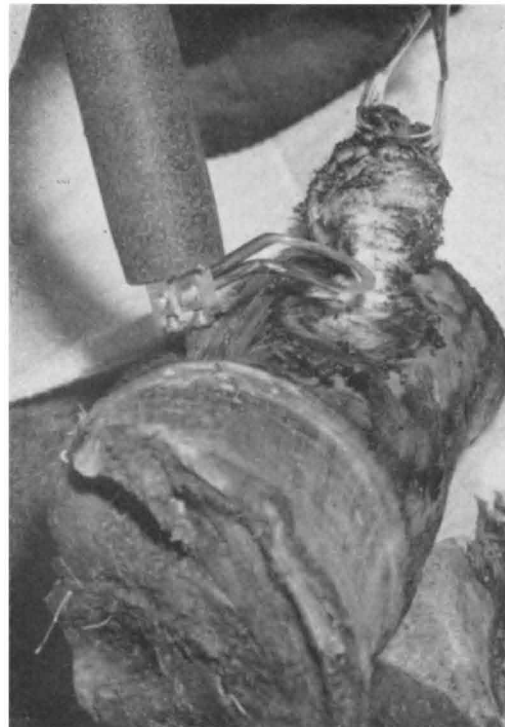

Fig. 4. Removing the Fibroma by Cautery.

was assured. It was also hoped that the cautery would kill any neoplastic cells left behind. A sulfanilamide pack was then applied and 1,500 units of tetanus antitoxin were administered subcutaneously.

The neoplasm was found to be an infected fibroma measuring about 5 cm. in diameter. It appeared to be only an involvement of the integument commune. It is seldom that growths of this type recur. A very slight thickening will