

1968

A Case of Hepatic Cirrhosis and Obstructive Icterus in the Canine

Mark Rogers
Iowa State University

Follow this and additional works at: http://lib.dr.iastate.edu/iowastate_veterinarian

 Part of the [Small or Companion Animal Medicine Commons](#), and the [Veterinary Pathology and Pathobiology Commons](#)

Recommended Citation

Rogers, Mark (1968) "A Case of Hepatic Cirrhosis and Obstructive Icterus in the Canine," *Iowa State University Veterinarian*: Vol. 30 : Iss. 1 , Article 2.

Available at: http://lib.dr.iastate.edu/iowastate_veterinarian/vol30/iss1/2

This Article is brought to you for free and open access by the Student Publications at Iowa State University Digital Repository. It has been accepted for inclusion in Iowa State University Veterinarian by an authorized editor of Iowa State University Digital Repository. For more information, please contact digirep@iastate.edu.

A Case of Hepatic Cirrhosis and Obstructive Icterus in the Canine

by Mark Rogers

HISTORY AND CLINICAL SIGNS

On September 1, 1967 an eight year old spayed female Dachshund was presented to the Iowa State University Veterinary Clinic with a history of progressively losing condition. The owners remarked that she had been in good health and had just begun to lose weight recently. They also stated that her appetite was poor and that she had frequent periods of constipation characterized by scanty amounts of clay-colored feces.

Physical examination of the patient revealed that she was in poor condition, seemed to have an enlarged liver upon abdominal palpation, and icterus was evidenced by yellowing of the oral mucous membranes and sclera. Her rectal temperature was 103° F.

CLINICAL PATHOLOGY

In the next seven days several clinical pathology tests were performed and the following results were obtained:

DATE	TEST	RESULT	NORMAL (1,2)
9-1-67	Hemoglobin	20.59gm%	12-18gm%
9-1-67	PCV	58%	40-55%
9-1-67	White Count	9,100/cu.mm.	9,000-1,300°/cu.mm.
9-1-67	Differential	—	—
	Eos.	1%	3%-6%
	Band	8%	1%-5%
	Seg	80%	50%-73%
	Mono	1%	1%-8%
	Lymph	10%	10%-40%
9-1-67	SGPT	325 Sigma units	10-25 Sigma units
9-5-67	van den Bergh conjugated	20mg.%	.06-.14mg.%
	free	14mg.%	.06-.95mg.%
	total	34mg.%	.20-1.0mg.%
9-8-67	BSP dye	78% in 45 min.	less than 1.5% in 45 min.

* Mr. Rogers is a senior in the College of Veterinary Medicine, Iowa State University.

The results of the complete blood count did not reveal much deviation from normal except for a possible dehydration as indicated by the increased packed cell volume (PCV) and hemoglobin values.

The van den Bergh test showed greatly increased amounts of both conjugated and free bilirubin in the serum. Whenever 50% (or greater) of the total serum bilirubin is of the conjugated variety, hepatocellular necrosis should be suspected. In extrahepatic biliary obstruction the level of conjugated bilirubin is even more elevated but some free bilirubin is usually present.² In this case 58.6% was conjugated, and either biliary obstruction or both obstruction and cellular necrosis were considered as possible causes of the icterus.

The elevated Serum Glutamic-Pyruvic Transaminase (SGPT) level indicates some degree of hepatocellular necrosis.

The Bromosulphophthalein (BSP) dye retention test results were far above normal indicating liver dysfunction involving either hepatic blood flow; the process of cellular uptake, conjugation and excretion of BSP; or patency of the bile passages.²

DIAGNOSIS AND TREATMENT

From the history, clinical signs, and results of clinical pathology a tentative diagnosis of liver cirrhosis with secondary biliary obstruction was made. To more accurately determine the extent of liver damage and prognosis, a needle biopsy was

taken of the liver through the right seventh intercostal space and sent to the Veterinary Pathology Department for histologic section and interpretation.

The patient was treated daily with Bio-Delta®,* (1cc.); crude liver extract, (1cc.); Ambex®,* (50cc.); and fluids in the form of 5% dextrose in half-strength saline (as indicated) for twelve days beginning on the day of admittance. During this time her condition showed little improvement.

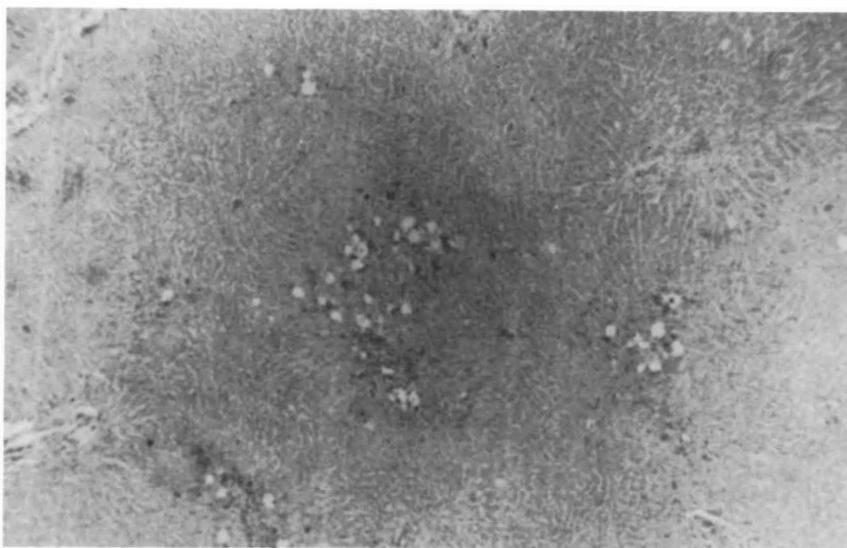


Figure 1. Photomicrograph of liver section taken at necropsy showing portal cirrhosis centrolobular fibrosis, and hepatic necrosis. x50

BIOPSY REPORT

On September 12, 1967, the biopsy report was returned with a diagnosis of severe portal cirrhosis characterized by portal fibrosis, infiltration with lymphoid cells, centrolobular fibrosis, marked canalicular retention of bile, and hepatic degeneration and necrosis.

A grave prognosis was given and euthanasia was recommended to the owners.

NECROPSY

Permission for euthanasia was obtained and it was performed on September 12.

* Bio-Delta®: Procain penicillin in dihydrostreptomycin with prednisilone. The Upjohn Company, Kalamazoo, Mich.

Ambex®: Amino acid solution with electrolytes, vitamin B complex and dextrose (5%). Corvel Division of Eli Lilly and Co., Indianapolis, Indiana.

The results of the post-mortem examination were as follows:

There was yellowing of the sclera of the eye, the mucous membranes of the mouth, the subcutaneous fat, and the abdominal fat. The omentum was adhered to a two centimeter diameter area of the middle of the visceral surface of the spleen and less strongly to the liver and diaphragm ventrally. Several adhesions contained masses of firm, reddish-brown material.

The respiratory system showed no gross lesions.

Within the cardiovascular system, the atrioventricular valves bore nodular thickenings marked mostly on the left, and the chordae tendinae were shortened. The intima of the anterior half of the aorta was roughened and sclerotic, and the entire aorta was yellowish in color.

Within the digestive system, the esophageal mucosa appeared yellowish, and the stomach contained about twenty-five cc. of thick, red fluid. The mucosa of the duodenum and patches of the jejunum and ileum were somewhat reddened. The liver was grayish brown, firm and friable with a slightly granular surface and a light brown background bearing dark brown spots corresponding to the hepatic lobules. The gall bladder was thickened and opaque.

Within the musculoskeletal system, the ribs were bowed slightly inward at their ventral ends, and the medial surfaces felt roughened.

The urogenital system showed no gross lesions.

The only gross lesion in the nervous system was markedly yellow but transparent, cerebrospinal fluid.

Within the endocrine system, the parathyroid glands were enlarged to a size of

DISCUSSION

Whenever disease of the liver is suspected certain liver function tests are indicated, but it must be kept in mind that the liver is an organ of many functions and that in liver disease usually several, but rarely all, functions are disrupted. Results of clinical pathology tests must then, be closely associated with observed clinical signs in order to make an accurate diagnosis.³

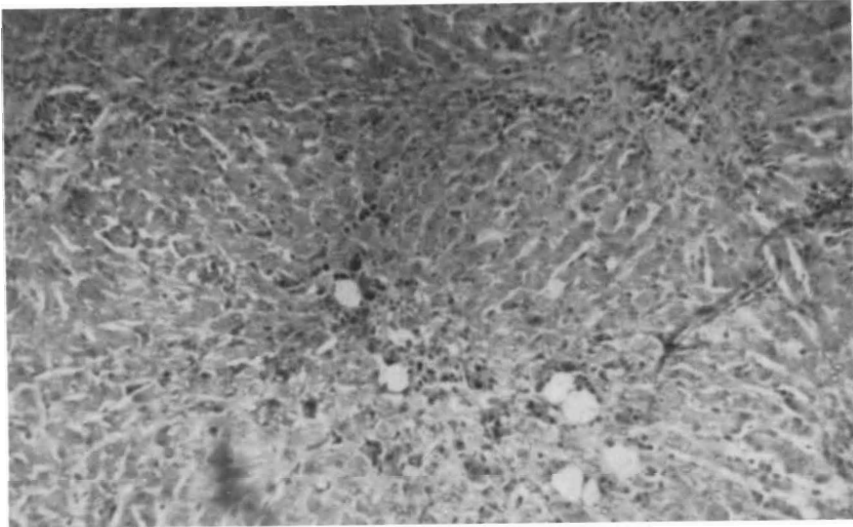


Figure 2. Photomicrograph of liver section taken at necropsy showing portal cirrhosis with infiltration of lymphoid and plasma cells. Centrolobular fibrosis and degeneration is also evident. x110

two to three mm. in diameter. The thyroid glands were pale brown in color but otherwise normal. The medulla of the left adrenal gland contained a pinkish nodule approximately three mm. in diameter near its anterior end.

The tentative diagnosis made on post-mortem examination was infectious canine hepatitis, resolved nutritional secondary hyperparathyroidism, adrenal cortical nodular hyperplasia, and organized blood clots in the peritoneal cavity.

Histologic section of the tissues taken at post-mortem did not confirm the diagnosis of infectious canine hepatitis since no intranuclear inclusion bodies were seen in the hepatic cord cells. No specific etiologic diagnosis was offered for the liver lesions, but the rest of the tentative diagnosis was considered to be correct.

When icterus is present in an animal it is an indication of excess bilirubin, either "free" or "conjugated," in the serum. The van den Bergh test was used to measure the total serum bilirubin and determine specific quantity of each type. A predominance of free bilirubin indicates that excessive intravascular hemolysis is probably the cause, and, as previously mentioned, if over half of the total is conjugated bilirubin, then biliary obstruction or hepatocellular necrosis may be the primary cause. When obstruction alone is the cause there is usually a great predominance of conjugated bilirubin with only small amounts of free present.² In this case, 58.6% of the 34.2mg.% total serum bilirubin was of the conjugated type. This result, when associated with the clinical signs, especially the clay-colored feces, suggests biliary obstruction.

tion is present in addition to some degree of hepatic necrosis.

To determine the prognosis in a case such as this, two other liver function tests are especially useful. The serum transaminase (SGPT) determination measures the level of circulating transaminase. This enzyme is normally present in the hepatic parenchymal cells and is liberated into the blood in liver necrosis. The test is "liver specific" only in the dog, cat, and man. A value in this case of 325 Sigma units indicates moderate to severe liver necrosis although, according to Cornelius, values above 1,000 Sigma units are not uncommonly observed.²

The Bromosulphophthalein (BSP) dye clearance test is one of the most sensitive of the liver function tests. It will often detect slight liver dysfunctions whereas other tests usually require a much greater degree of liver pathology to show a positive result. It is a measure of hepatic blood flow; uptake, conjugation, and excretion of BSP by the liver cells; and patency of the bile passageways. It will only be elevated in the presence of liver fibrosis or necrosis.^{1, 2} For this reason it is recommended by Cornelius that SGPT determination be used in conjunction with it to indicate the nature of liver disease.² The BSP result in this case (78% in 45 minutes) indicates severe liver damage probably in the nature of necrosis (elevated SGPT) but the possibilities of concurrent fibrosis is not ruled out.

An unfavorable prognosis was given in this case as it is in most canine liver disease owing to the fact that it is usually well advanced before it is diagnosed.

Portal cirrhosis of the liver in dogs, as in any animal, is thought to be due to chronic liver toxicity causing continued irritation and a resulting proliferation of fibrous connective tissue in the portal triads following the death of hepatic cord cells. In the canine, these toxins are usually either chemical toxins ingested over a period of time (e.g. tetrachlorethylene and carbon tetrachloride anthelmintics), or of a chronic "metabolic" nature as might be produced by some forms of gastro-enteritis or any number of infectious diseases. Malnutrition in the dog, especially diets low in

protein and choline, are usually concurrent with the above causes.⁴ No specific cause could be found in this case.

The usual effects of portal cirrhosis are those which reflect interference with portal circulation, i.e. passive congestion and edema of the spleen, stomach and intestinal tract. Jaundice only appears when the fibrosis is so severe that it constricts and obstructs the bile ducts and these advanced cases are usually considered terminal. In this case little congestion and edema was noted in the abdominal viscera, but the marked canalicular retention of bile indicates the severity of cirrhosis. One other important feature of the histologic section is the presence of lymphoid cell infiltration in the portal areas. This is an indication that the inflammatory process was still active at the time the biopsy was taken.⁴

The recommended treatment for less severe cases of cirrhosis is directed primarily at correction of dietary deficiencies. A diet high in high quality protein (1 gm./lb./day) and carbohydrates (3 gm./lb./day) and low in fats (.5 gm./lb./day) is recommended. Sorbital may be given at the rate of .5 grams per feeding to increase absorption of fats if desired. Supplementation of B complex and fat soluble vitamins is also indicated.³

Medical treatment should consist of administration of lipotropic agents such as choline, methionine or lecithin at the rate of .5 to 2 grams daily to control fatty infiltration of the liver, and liberal use of liver extract, especially intravenously, is often helpful. In patients with persistent edema and ascites the salt content of the diet should be restricted as should the fluid intake. Biweekly injections of mercurial diuretics may be used to help control this, but signs of dehydration should be watched for.³

REFERENCES

1. Benjamin, M. M., *Outline of Veterinary Clinical Pathology*. Second edition. Iowa State University Press, Ames, Iowa. 1965.
2. Cornelius, C. E., and Kaneko, J. J., *Clinical Biochemistry of Domestic Animals*. Academic Press, New York, New York, 1963.
3. Hoskins, H. Preston, Lacroix, J. V., and Mayer, K., (editors), *Canine Medicine*. A.V.P. Inc., Santa Barbara, Calif. 1966.
4. Smith, H. A., and Jones, T. C., *Veterinary Pathology*. Lea and Febiger, Philadelphia, Penn. 1961.