

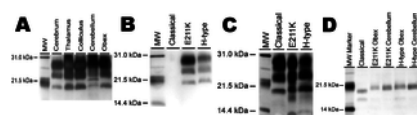


Correction: Clinical and Pathologic Features of H-Type Bovine Spongiform Encephalopathy Associated with E211K Prion Protein Polymorphism

Justin J. Greenlee, Jodi D. Smith, M. Heather West Greenlee, Eric M. Nicholson

Published: January 17, 2013 • <https://doi.org/10.1371/annotation/256348ad-e2eb-40ef-8f0c-fa14475ea5fb>

There was an error in Figure 5, panel A. Please see the corrected Figure 5 here:



Citation: Greenlee JJ, Smith JD, West Greenlee MH, Nicholson EM (2013) Correction: Clinical and Pathologic Features of H-Type Bovine Spongiform Encephalopathy Associated with E211K Prion Protein Polymorphism. PLoS ONE 8(1): 10.1371/annotation/256348ad-e2eb-40ef-8f0c-fa14475ea5fb. <https://doi.org/10.1371/annotation/256348ad-e2eb-40ef-8f0c-fa14475ea5fb>

Published: January 17, 2013

Copyright: © 2013 . This is an open-access article distributed under the terms of the Creative Commons Attribution License, which permits unrestricted use, distribution, and reproduction in any medium, provided the original author and source are credited.

Competing interests: No competing interests declared.

