

2002

Repeated intravenous doses of all-trans-retinoyl β -D-glucuronide is not effective in the treatment of bacterial bronchopneumonia in lambs but is devoid of gross and acute toxicity

Jack M. Gallup

Iowa State University, eag@iastate.edu

Branka Grubor

Iowa State University


Arun B. Barua

Iowa State University

Gholamreza Mohammadi

University of Ferdousi

Follow this and additional works at: http://lib.dr.iastate.edu/vpath_pubs

 Part of the [Biochemistry Commons](#), [Biophysics Commons](#), [Molecular Biology Commons](#), and the [Veterinary Pathology and Pathobiology Commons](#)

See next page for additional authors.

The complete bibliographic information for this item can be found at http://lib.dr.iastate.edu/vpath_pubs/38. For information on how to cite this item, please visit <http://lib.dr.iastate.edu/howtocite.html>.

Repeated intravenous doses of all-trans-retinoyl β -D-glucuronide is not effective in the treatment of bacterial bronchopneumonia in lambs but is devoid of gross and acute toxicity

Abstract

Background

All-trans-retinoyl β -D-glucuronide, a water-soluble glucuronic acid conjugate of all-transretinoic acid, has demonstrated high biological activity and low toxicity in most in vitro and in vivo models. Since the reparative effects of retinoids on epithelium are well-known, our aim was to study the effect(s) of intravenously-administered all-trans-retinoyl β -D-glucuronide in lambs with chronic bacterial bronchopneumonia.

Material/Methods

Two groups of lambs were inoculated intrabronchially with either pyrogen-free saline or Mannheimia haemolytica. Thirty-three days later, lambs were injected four times at five-day intervals with 2 mL of 116 mM all-trans-retinoyl β -D-glucuronide (6.0–9.3 μ mol/kg or 2.86–4.42 mg/kg animal body weight) in dimethyl sulfoxide, or dimethyl sulfoxide alone. Animal behavior and signs of clinical illness were logged daily. Lung and liver samples were assessed for histopathology, while serum and liver samples were extracted for retinoids and analyzed by reversed-phase gradient high-performance liquid chromatography.

Results

Repeated injections of highly concentrated all-trans-retinoyl β -D-glucuronide did not cause changes in appetite, activity or other behaviors nor did it cause histologic lesions in liver and lung. However, it had no effect on resolution of lung lesions resultant of chronic Mannheimia haemolytica bronchopneumonia.

Conclusion

Repeated intravenous administration of high amounts of all-trans-retinoyl β -D-glucuronide to lambs did not elicit signs of gross or microscopic toxicity. However, administering all-transretinoyl β -D-glucuronide too late in the progression of bacterial pneumonia is thought to be the main reason for its lack of effect in this model. A retinoid lactone derivative was detected in sheep serum and liver several days after treatment.

Keywords

retinoids, RAG, toxicity, broncopneumonia, intravenous injection, lesions, Biochemistry Biophysics and Molecular Biology

Disciplines

Biochemistry | Biophysics | Molecular Biology | Veterinary Pathology and Pathobiology

Comments

This article is from *Medical Science Monitor* 8, no. 9 (2002): 345–353.

Rights

Works produced by employees of the U.S. Government as part of their official duties are not copyrighted within the U.S. The content of this document is not copyrighted.

Authors

Jack M. Gallup, Branka Grubor, Arun B. Barua, Gholamreza Mohammadi, Kim A. Brogden, James A. Olson,
and Mark R. Ackermann

Received: 2002.04.05
Accepted: 2002.07.10
Published: 2002.09.09

Repeated intravenous doses of all-*trans*-retinoyl β -D-glucuronide is not effective in the treatment of bacterial bronchopneumonia in lambs but is devoid of gross and acute toxicity

Authors' Contribution:

- A** Study Design
- B** Data Collection
- C** Statistical Analysis
- D** Data Interpretation
- E** Manuscript Preparation
- F** Literature Search
- G** Funds Collection

Jack M. Gallup¹, Branka Grubor¹, Arun B. Barua², Gholamreza Mohammadi³, Kim A. Brogden⁴, James A. Olson², Mark R. Ackermann¹

¹ Department of Veterinary Pathology, College of Veterinary Medicine, Iowa State University, Ames, Iowa, USA

² Department of Biochemistry and Biophysics and Molecular Biology, College of Liberal Arts and Sciences, Iowa State University, Ames, Iowa, USA

³ Department of Clinical Studies, School of Veterinary Medicine, University of Ferdousi, Mashhad, Iran

⁴ Respiratory Diseases of Livestock Research Unit, USDA/ARS-National Animal Disease Center, Ames, Iowa, USA

Source of support: This work was supported by USDA/NRI Project # 99-35204-7681

Summary

Background:

All-*trans*-retinoyl β -D-glucuronide, a water-soluble glucuronic acid conjugate of all-*trans*-retinoic acid, has demonstrated high biological activity and low toxicity in most *in vitro* and *in vivo* models. Since the reparative effects of retinoids on epithelium are well-known, our aim was to study the effect(s) of intravenously-administered all-*trans*-retinoyl β -D-glucuronide in lambs with chronic bacterial bronchopneumonia.

Material/Methods:

Two groups of lambs were inoculated intrabronchially with either pyrogen-free saline or *Mannheimia haemolytica*. Thirty-three days later, lambs were injected four times at five-day intervals with 2 mL of 116 mM all-*trans*-retinoyl β -D-glucuronide (6.0–9.3 μ mol/kg or 2.86–4.42 mg/kg animal body weight) in dimethyl sulfoxide, or dimethyl sulfoxide alone. Animal behavior and signs of clinical illness were logged daily. Lung and liver samples were assessed for histopathology, while serum and liver samples were extracted for retinoids and analyzed by reversed-phase gradient high-performance liquid chromatography.

Results:

Repeated injections of highly concentrated all-*trans*-retinoyl β -D-glucuronide did not cause changes in appetite, activity or other behaviors nor did it cause histologic lesions in liver and lung. However, it had no effect on resolution of lung lesions resultant of chronic *Mannheimia haemolytica* bronchopneumonia.

Conclusion:

Repeated intravenous administration of high amounts of all-*trans*-retinoyl β -D-glucuronide to lambs did not elicit signs of gross or microscopic toxicity. However, administering all-*trans*-retinoyl β -D-glucuronide too late in the progression of bacterial pneumonia is thought to be the main reason for its lack of effect in this model. A retinoid lactone derivative was detected in sheep serum and liver several days after treatment.

key words:

retinoids • RAG • toxicity • bronchopneumonia • intravenous injection • lesions

Full-text PDF:

http://www.MedSciMonit.com/pub/vol_8/no_9/2658.pdf

Word count:

4752

Tables:

1

Figures:

4

References:

55

Author's address:

Jack M. Gallup, Department of Veterinary Pathology, Iowa State University, 2737 College of Veterinary Medicine, Ames Iowa, 50011-1250 USA, email: eag@iastate.edu or mackerma@iastate.edu

BACKGROUND

Vitamin A specifically refers to vitamin A alcohol, retinol (ROH) and its isomers, but also represents a larger group of compounds, known collectively as retinoids, which have been most recently defined as compounds structurally similar to retinol, or that elicit specific biological responses by binding to and activating a specific receptor or set of receptors [1,2]. All-*trans*-retinoic acid (RA) mediates its biologic effect by binding to nuclear retinoic acid receptors (RAR- α , β , γ) and/or retinoid X receptors (RXR- α , β , γ) [3]. An *in vitro* study performed on rabbit tracheal epithelial cells showed that receptor agonists act as metaplastic inhibitors with RAR α and RAR β , and RXRs to a lesser extent, while RAR α induces apoptosis in proliferating epithelial cells in the S-phase [3]. To increase the transcription of their target genes, these nuclear receptors bind specific DNA sequences (retinoic acid response element; [4,5]). Because retinoids decrease growth of epithelial cells and fibroblasts, enhance differentiation, and reduce collagen synthesis [6], they have a profound direct effect on lung cells and are potentially therapeutic for pulmonary diseases. In the lung, retinoids and retinoic acid receptors are present in high levels during fetal maturation, but decrease rapidly after birth along with retinoic acid receptors. During cell injury and in immature cells, retinoid receptors are again upregulated. In neonatal rats, RA enhances formation of alveoli, increases the number of alveoli, and abrogates elastase-induced pulmonary emphysema [7,8]. Retinoids enhance development of the fetal lung; RA also appears to have an effect on both the pulmonary mesenchyma and epithelia [9]. RA accelerates lung septation and branching resulting in increased formation of alveoli [9,10], and lung growth is enhanced by RA in animals after experimental pneumonectomy [11]. Vitamin A deficiency results in reduced lung elastin, and reduced surfactant biosynthesis and ornithine decarboxylase activity by respiratory type II cells [9,12]. And rats sustained on a vitamin A-deficient diet exhibit inflammation of the lungs and emphysema (as evidenced by increased size of air spaces distal to the terminal bronchiole with thinning and partial or total destruction of septal wall) indicating that a lack of vitamin A results in emphysemic lungs [12]. Additionally, β -carotene (provitamin A) supplemented diet decreases pneumotoxin monocrotaline (MCT) induced inflammation in rat lung [13]. Currently, the effect of retinoids on lung repair following bacterial infection has not been determined.

Although RA has already shown to be effective in treating acute promyelocytic leukemia (APL) and cystic acne in humans, the use of RA can result in adverse side effects [14]. A naturally-occurring glucuronic acid conjugate of RA, all-*trans*-retinoyl β -D-glucuronide (RAG) has potential advantages over RA and other retinoids in solubility and toxicity, and for the first time demonstrated its potent biological activity and lack of toxicity in the differentiation of HL-60 cells into normal neutrophils [15,16]. Though RAG was subsequently shown to be transported to the nucleus (in HL-60 cells) [17], it is not known with certainty whether RAG is biologically active *per se* or by virtue of its hydrolysis to small amounts of RA. RA can be

detected in small amount after administration of RAG by intraperitoneal (IP), intramuscular (IM) or intravenous (IV) injection [18–21]. Therefore, it can be expected that RAG may serve as a non-toxic pro-RA. Unlike most retinoids, including RA, which are lipid soluble, RAG is water-soluble [22]. This property makes it ideal for IV or aerosol application. Additionally, RAG is non-toxic when either absorbed through the skin after topical applications, or by the digestive tract following oral administrations, while most retinoids are toxic at high doses. Further, RAG seems not to induce its own metabolism e.g. during two-month daily subcutaneous injections of RAG into rats, peak plasma levels remain elevated. RA, on the contrary, rapidly induces its own metabolism [23], and therefore greatly limits its own activity. Even though both RA and RAG achieve peak plasma concentrations within 1–2 hours after subcutaneous injections of RAG into rats, RA (now a RAG metabolite) is cleared rapidly from the plasma whereas RAG is eliminated much more slowly. RAG has also been reported to be roughly sixteen times less potent in inducing teratogenicity than RA [24]. When RAG was administered orally to pregnant Sprague-Dawley rats (110–380 μ mol/kg animal body weight) on day 8.5 of gestation, it did not produce teratogenic effects, while RA did. This is due to a much slower rate of RAG absorption by the GI, its slower rate of hydrolysis to RA, and its limited passage into the embryo. However, Nau et al. have shown that smaller doses of RAG (20 μ mol/kg animal body weight) administered subcutaneously to pregnant NMRI mice on day 11 of gestation, resulted in high incidence of teratogenicity. The discrepancy between these results might be explained by a higher rate of RAG conversion to the teratogenic RA in NMRI mice as compared to Sprague-Dawley rats or even other strains of mice, i.e. ICR mice. Lastly, RAG is similar in efficacy to RA in treatment of acne in humans, but without the same side effects [25].

The purpose of this study was to: 1) develop a formulation in which high concentrations of RAG can be injected IV, and 2) determine if repeated doses of RAG can be tolerated by sheep, and 3) determine if such treatments are beneficial in repair of lung lesions resultant of chronic bacterial bronchopneumonia.

MATERIAL AND METHODS

Clearance to use animals

Animal use was approved by Iowa State University's Animal Care and Use Committee.

Synthesis of all-*trans*-retinoyl β -D-glucuronide

RAG used in this study was chemically synthesized in high yields with the use of the phase-transfer catalyst, tetra-butylammonium hydroxide according to previously published methods [26].

IV injection considerations

IV injection into the external jugular vein was chosen as the method of delivery because: 1) it is convenient for

large animals, 2) most of the blood carrying RAG in the external jugular vein goes directly to the heart and then the lung, thus allowing recently injected RAG to rapidly enter the pulmonary circulation and avoid the systemic circulation, 3) the amount of RAG injected intravenously and entering the circulation can be readily quantified (in comparison to the difficulties expected when trying to quantify amounts of RAG delivered by aerosolic application; losses of RAG in the nasal cavity, by animal sneezing or ingestion, external losses etc.). The initial concentration we desired to attain in sheep plasma was 100 μ M, a dose based on studies in rats [see again reference 21]. Because we desired IV injections, we sought to concentrate RAG into the smallest, least invasive volume of vehicle; a volume which would be reasonable to inject into both young and adult sheep and other animals species. Although significantly water-soluble, RAG, like other retinoids, is highly soluble in DMSO, and after attempting several RAG formulations in aqueous buffers with and without DMSO, we decided to use 2 mL of DMSO as the dosage vehicle.

Formulation of RAG for IV injections

A stock solution of 116 mM RAG in 79 mL of 99.9% DMSO (Sigma, St. Louis, MO, Cat. No. D-8418) was carefully prepared under yellow light using freshly-synthesized, RAG. The concentration of the RAG stock solution was checked by measuring several serial methanolic dilutions of it in a spectrophotometer. The RAG/DMSO injection solution was stored at 4°C in an amber glass bottle (sealed under argon), and for injections, only the amount needed for each of the 4 days pre-designated for RAG/DMSO administration was taken from the bottle (by pouring the desired volume into an aluminum foil-wrapped 50 mL conical centrifuge tube).

Experimental design

Weaned lambs (n = 3 or 4/group) (3 months of age, either sex) were separated into four groups (Table 1), based on the type of intrabronchial inoculations and IV injections they received. Immediately prior to intrabronchial injections, sheep were sedated with xylazine (0.1 mg/kg, IV), then they received either 5 mL pyrogen-free saline (PFS; Groups 1 and 2) or *Mannheimia haemolytica* in PFS (5 mL 1×10^9 cfu/mL; Groups 3 and 4). The PFS and *M. haemolytica* were deposited in the right tracheal bronchus of each animal with a fiberoptic bron-

choscope as described previously [27,28]. At days 33, 38, 42 and 47 after the intrabronchial inoculations, sheep received IV injections of 2 mL of either DMSO alone (Groups 1 and 3) or DMSO containing 116 mM RAG (Groups 2 and 4) in the external jugular vein. Serum, respiratory tissues and liver were collected 50 days after the intrabronchial inoculations. RAG/DMSO-treated lambs received a calculated initial average plasma concentration of 147 μ M RAG; the highest calculated initial plasma concentration of RAG in any RAG/DMSO-treated lamb was 193 μ M.

Injections

Each lamb received a constant 2 mL of 116 mM RAG in DMSO by IV injection regardless of body weight during the intrajugular administrations (and the RAG/DMSO was mixed with each sheep's blood within the injection syringe prior to each injection to avoid 'clustering' of RAG in the bloodstream). Among lambs that received the 2 mL injections of 116 mM RAG/DMSO, animal body weights ranged from 25 kg to 38.64 kg, which accounted for calculated initial plasma concentrations of RAG ranging from 125 μ M to 193 μ M. Sheep plasma volume (in liters) was calculated to be 0.048 fraction of each animal's body weight; 8% of the body weight was the calculated blood volume and 60% of the blood volume was the calculated plasma volume in each case.

Animal behavioral observations

Animals were monitored twice daily for respiratory distress (increased respiration, coughing and dyspnea), and general behavior (eating, drinking, sleeping, and interactions with pen-mates). Any changes were logged in a record book attached to the door of each room. Clinical symptoms (slight fever, increased respiration and mild coughing) were first detected during days 1–3 post inoculation with *M. haemolytica*.

Preparation and storage of serum and liver samples

10 mL of blood was collected from the jugular vein of each animal prior to euthanasia, the blood was allowed to clot and the serum was clarified by spinning at 200 x g in a tabletop centrifuge for 15 minutes at room temperature after which the (top) serum layer (2–4 mL) was removed and stored in cryo-vials at –80°C until needed for retinoid extraction. Prior to being extracted for retinoids, liver samples were collected on the day of necropsy, transferred immediately to cryo-vials and stored at –80°C until needed.

Preparation of slides for microscopic histopathology

At necropsy, animals were euthanized by IV injection with an overdose of sodium pentobarbital immediately prior to tissue collection. Lung tissues were collected from the central area of the inoculation site of each *M. haemolytica*-treated animal and corresponding sections were taken from saline-treated control animals. Tissues were fixed in 10% neutral-buffered formalin for 24–48 hours. Following fixation, tissues were processed for 48

Table 1. Experimental design for injections of RAG into sheep with and without chronic bacterial bronchopneumonia.

Group no.	No. of sheep	Intrabronchial inoculation	Intravenous inoculation	Initial [RAG] in plasma (μ M)
1	3	PFS*	DMSO	0
2	4	PFS	DMSO/RAG**	146.0 \pm 31.7***
3	3	<i>M. haemolytica</i>	DMSO	0
4	4	<i>M. haemolytica</i>	DMSO/RAG	147.5 \pm 13.2

* PFS denotes pyrogen-free saline; ** 2 mL of 116 mM RAG dissolved in 99.9% DMSO; *** Values are expressed as mean \pm SD

hours in an automated tissue processor and embedded in paraffin. Embedded tissues were then sectioned (3–5 μm) by microtome (according to standard histopathology procedures) and affixed to silanated glass specimen slides. Sections were then stained with hematoxylin and eosin (H&E) and evaluated for histological changes by light microscopy.

Extraction of retinoids from serum

Retinoids from serum were extracted according to published procedure [29,30]. In brief, serum was extracted with ethyl acetate and hexane in presence of ethanol containing BHT, and acetic acid. Retinyl acetate was used as the internal standard. The extract was evaporated to dryness under argon in a water bath at 39°C. The final dried residue was dissolved in 100 μL of (2:1) 2-propanol/dichloromethane and 90 μL of the resulting solution was subjected to reversed-phase gradient HPLC analysis.

Extraction of retinoids from liver

The procedure for extraction of retinoids from liver was the same as published [30]. In brief, 0.5 g of liver was extracted with a mixture of 2-propanol/dichloromethane ($\times 3$) in the presence of retinyl acetate and BHT (internal standard and antioxidant, respectively). The extract was then evaporated to dryness under argon, and then dissolved in 500 μL of (1:1) 2-propanol/dichloromethane and any remaining debris at this point was centrifuged out. The clarified solution was transferred to a clean tube and 90 μL was subjected to reversed-phase gradient HPLC analysis.

Saponification of retinoid extracts

A dried retinoid extract (of serum or liver, etc.) was saponified by reflux with methanolic sodium hydroxide in the presence of a trace amount of BHT. The retinoids were extracted, after acidification with dilute acetic acid, with a mixture of ethyl acetate and hexane. The organic phase was evaporated to dryness at 39°C under argon. The final residue was dissolved in 100 μL of (2:1) 2-propanol/dichloromethane (for extracts from liquid samples, i.e. serum, urine or bile) or 500 μL of (2:1) 2-propanol/dichloromethane (for extracts from liver), and 90 μL of each was subjected to reversed-phase gradient HPLC analysis.

β -Glucuronidase treatment of retinoid extracts

Incubation of retinoid extracts with β -glucuronidase enzyme was carried out according to published procedure [31]. Final extract residues were dissolved in 100 μL of (2:1) 2-propanol/dichloromethane (for extracts from liquid samples, i.e. serum, urine or bile) or in 500 μL of (2:1) 2-propanol/dichloromethane (for extracts from liver), and 90 μL of each was subjected to reversed-phase gradient HPLC analysis.

Reversed-phase gradient HPLC

For analysis of reference compounds, serum and liver retinoids, a previously published reverse-phase gradient HPLC procedure was used (see [29]).

RESULTS

Animal behavioral studies

All lambs inoculated with *M. haemolytica* developed respiratory changes (increased respiratory rate, some coughing) typical of *Mannheimia haemolytica*-induced pneumonia for up to 7 days after infection. Lambs receiving pyrogen-free saline lacked any changes and appeared normal. After 7–14 days, lambs begin to develop chronic bronchopneumonia in this model [32], and lack clinical disease (changes in respiration rate, body temperature, coughing or wheezing etc.). At the time of RAG/DMSO or DMSO administration in this study, lambs lacked signs of clinical disease and behavioral abnormalities. There was no increase or decrease in water or food consumption or alterations in sleep or other behavior. On one occasion, animals receiving RAG (both infected and uninfected) seemed to be 'more lively or energetic' than lambs receiving just DMSO.

Gross Pathology

There were no gross lesions in the abdomen and thorax of the control animals. Animals inoculated with *M. haemolytica* had focal areas of consolidation at the site of bacterial deposition. No other lesions were seen in any animal.

Histopathology

For histopathology, sections of lung from all bacteria-inoculated animals were found to contain lesions typical of chronic *M. haemolytica* bronchopneumonia. These lesions were characterized by marked multifocal thickening of alveolar walls by fibrous connective tissue and type II cell hypertrophy and hyperplasia as well as moderate to marked bronchiolar epithelial hyperplasia. Lungs of animals lacking *M. haemolytica* infection had only minimal to mild peribronchiolar and peribronchial infiltrates of lymphocytes and plasma cells. Animals receiving either RAG/DMSO or DMSO alone lacked additional microscopic lesions in respiratory tract including trachea and lung. There were also no microscopic lesions in the liver of any animal.

Reversed-phase gradient HPLC analysis

Analysis of retinoid standards yielded the typical retinoid elution profile characteristic of this HPLC method (Figure 1). Analysis of retinoid extracts from serum and liver showed that retinol and retinyl esters were the major retinoids in serum and liver, respectively (Figures 2 and 3). Neither RAG nor RA were detected in serum or liver samples collected 4 days after the last RAG injection. However, serum and liver extracts from RAG/DMSO-treated animals revealed a metabolite of

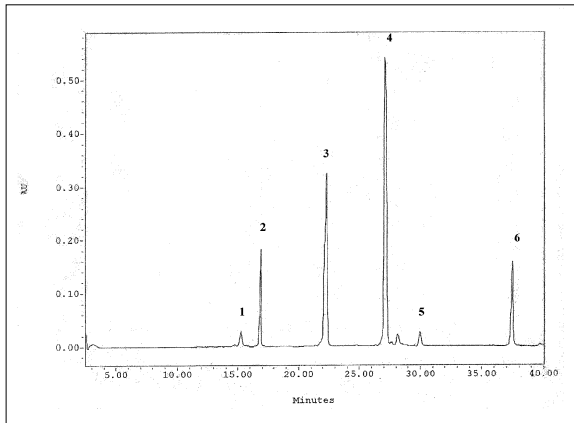


Figure 1. Reversed-phase gradient HPLC chromatogram of retinoid standards obtained at 329 nm. Peak identification: 1: all-trans-retinoyl β-D-glucuronide; 2: all-trans-retinoic acid; 3: all-trans-retinol; 4: all-trans-retinyl acetate; 5: all-trans-retinoyl β-D-glucuronolactone; 6: all-trans-retinyl palmitate.

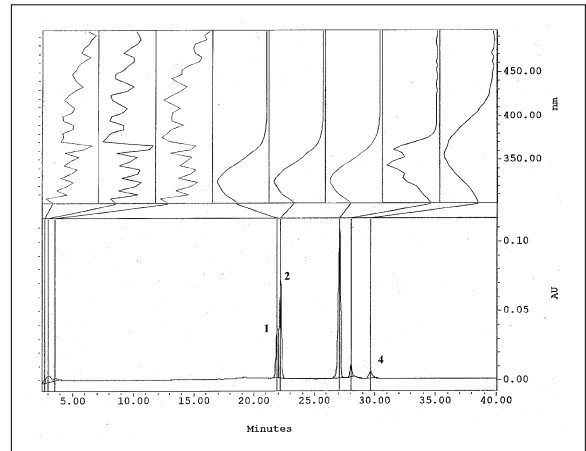


Figure 2. Reversed-phase gradient HPLC chromatogram of serum retinoid extract from a RAG/DMSO-treated lamb showing the accompanying spectrum index plot. Peak identification: 1: 13-cis-retinol; 2: all-trans-retinol; 3: retinyl acetate; 4: retinoyl β-D-glucuronolactone. (Sample was collected at necropsy 3 days after the final RAG/DMSO injection).

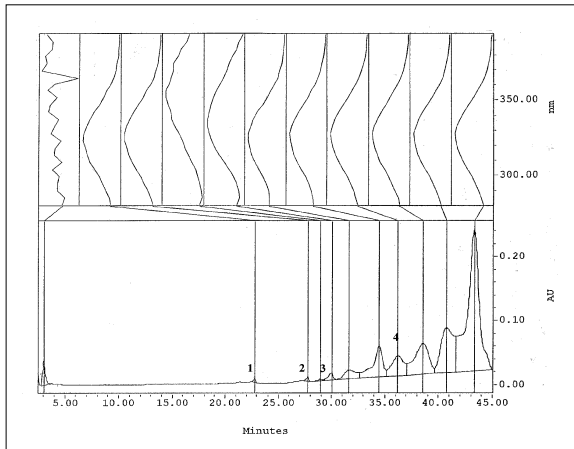


Figure 3. Reversed-phase gradient HPLC chromatogram of liver retinoid extract from a RAG/DMSO-treated lamb (before treatment with β-glucuronidase enzyme) showing the accompanying spectrum index plot. Peak identification: 1: retinol; 2: retinyl acetate; 3: retinoyl β-D-glucuronolactone; 4: retinyl palmitate. The common array of retinyl esters are observed between 31 and 45 minutes. (Sample was collected at necropsy 3 days after the final RAG/DMSO injection).

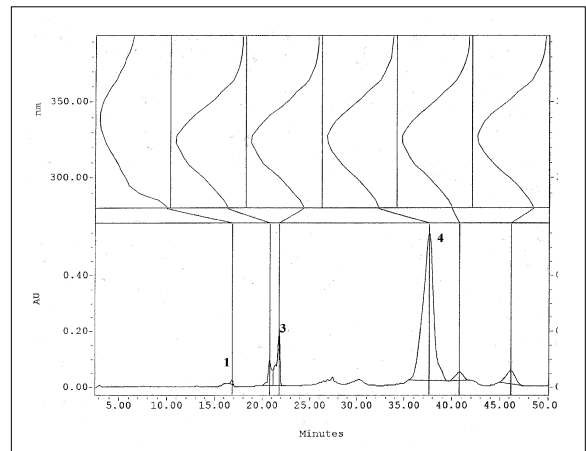


Figure 4. Reversed-phase gradient HPLC chromatogram of liver retinoid extract from a RAG/DMSO-treated lamb (after treatment with β-glucuronidase enzyme) showing the accompanying spectrum index plot. Peak identification: 1: retinoic acid; 2: 9-cis retinol; 3: all-trans-retinol; 4: retinyl palmitate.

all-trans-retinoyl β-D-glucuronide which was less polar than retinoyl β-D-glucuronide, retinoic acid, retinol and retinyl acetate (Figures 1-3). The metabolite showed an absorption spectrum similar to that of retinoyl β-D-glucuronide at 358 nm ($t_r = 29.7$ minutes). Serum and liver extracts from control (DMSO-treated) animals did not show this peak at 29.7 minutes. When serum or liver extracts of RAG/DMSO-treated lambs were incubated with β-glucuronidase or saponified, the metabolite peak at 29.7 minutes disappeared with the appearance of a peak at 16.8 minutes, which is the retention time of RA (Figure 4). The absorption spectrum of this peak was 338 nm indicating that it was RA. Because the

metabolite of RAG produced RA on treatment with β-glucuronidase, the metabolite must contain a glucuronic acid moiety. Because RAG can lactonize easily [23,34], and is much less polar than RAG, the metabolite has been tentatively identified as retinoyl β-glucuronolactone (RAGL). Retinoid extraction efficiencies from sheep serum and sheep liver were calculated to be $90.57 \pm 15\%$ and $75.82 \pm 18\%$, respectively.

DISCUSSION

Attempts to prepare highly concentrated solutions of RAG in 0.9% saline or PBS were not successful, although up to ~20 mM could be prepared in HPLC-grade water. Our original idea was to design a 5-mL parenteral aqueous formulation that delivered enough

RAG to 30–40 kg lambs to establish initial plasma concentrations of at least 100 μM , a concentration similar to that used for the treatment of elastase-induced lung injury in rats (and more directly comparable with what Ho et al. did in rats by administering 0.83, 1.67 and 2.5 mL injections of a 2.1 mM RAG/0.9% saline-20% (w/v) 2-hydroxypropyl β -cyclodextrin (HP β CD) formulation to establish 5, 10 and 15 $\mu\text{mol/kg}$ animal body weight, respectively (see again [21]). However, we found that we could not concentrate RAG enough in any aqueous medium alone to form the desired dose. Combinations of DMSO + 0.9% saline and DMSO + PBS pH 7.4 were attempted, but both saline and PBS severely limited RAG's solubility in DMSO. Since all retinoids, including RAG were known to be highly soluble in pure DMSO, the final vehicle chosen for this study was 99.9% DMSO lacking saline or PBS altogether. Although IV delivery of repeated high doses of RAG in DMSO has not been previously attempted, repeated IV administrations of RAG in 0.9% saline containing 20% (w/v) HP β CD to Sprague-Dawley rats has been performed, and the first detailed account of RAG pharmacokinetics described [see again ref. 21]. In our study, the average calculated initial plasma concentration of RAG established in lambs receiving 2 mL of 116 mM RAG in DMSO was 147 μM , which is nearly 7,300 times its normal average circulating level (19.95 \pm 9.45 nM) in mammalian serum (5–17 nM in human serum). After each injection (averaging 7.6 μmol RAG/kg sheep body weight), RAG could have been in part excreted into the bile and/or converted to RA, most likely by the activity of β -glucuronidase. This enzyme has been found in bovine liver [35], milk [36], seminal plasma [37]; in mono- and granulocytic blood cells from different domestic animal species including sheep [38]; in rabbits [39]; and rats. In the study with rats, where RAG was administered orally to vitamin A-deficient animals, RAG was rapidly hydrolyzed to RA, compared to vitamin A-sufficient rats where RAG and traces of RA appear only randomly in the plasma [40]. In target tissues, RA was found in higher amount than RAG in vitamin A-deficient rats, while RAG was much more abundant in vitamin A-sufficient rats. This change in RA/RAG ratio demonstrates the need for RA in target tissues. On the other hand, when no more RA is needed, it is sequestered by proteins and/or converted back into a physiologically less active form, RAG [41]. Both α and β -glucuronide conjugates of RA (the retinoyl glucuronides) and α and β -glucuronide conjugates of ROH (the retinyl glucuronides) were first recognized and identified as polar retinoid metabolites in the bile [42], small intestine [43], and liver [44] of the rat (in the presence of UDP-glucuronic acid, RA and ROH are converted to their respective α and β -glucuronides by UDP-glucuronosyltransferase enzyme (see [18]). Without being hydrolyzed to RA, these conjugates could serve as a source of RA.

Since we wished to observe the effect(s) of RAG/DMSO on chronic lung lesions, we administered RAG/DMSO late in the progression of experimentally-introduced *M. haemolytica* pneumonia. *Mannheimia haemolytica* is a common bacterial pathogen of the respiratory sheep and cattle throughout the world that can cause severe pneu-

monia and sometimes death. If animals survive initial infection, chronic lung lesions persist. These lesions impair gaseous exchange and can be a nidus for reinfections or secondary infections. *M. haemolytica* colonizes the tonsil and nasal cavity and at times of stress (shipping, overcrowding) or viral infection, proliferation of *M. haemolytica* increases. Vaccines are not fully protective.

For treatments, we administered 2 mL injections of 116 mM RAG/DMSO four times at 5-day intervals, with the first one being given 33 days post intrabronchial inoculations of either *Mannheimia haemolytica* or saline, and the last one being given 3 days before animal sacrifice. Clinical consequences of acute hypervitaminosis A, which include vomiting, stupor, papilledema [45], were not observed in RAG/DMSO-treated lambs. Animal behavior remained normal and constant throughout the studied period, and there were no thoracic or abdominal gross lesions. Histopathology of trachea, lung, and liver showed no significant differences between RAG/DMSO-treated and DMSO-treated lambs, illustrating the non-toxic feature of intravenously introduced RAG (and DMSO for that matter). Lesions of lung resultant of *M. haemolytica*-induced bronchopneumonia (characterized by microscopic inspection of hematoxylin and eosin-stained lung sections on glass slides) were identified as areas with pronounced multifocal alveolar-wall thickening (from build-up of fibrous connective tissue), and type II cell hypertrophy and hyperplasia, and moderate to severe bronchiolar epithelial cell hyperplasia. Lungs of animals lacking infection, whether treated with RAG/DMSO or just DMSO, had only minimal to mild peribronchiolar and peribronchial infiltrates of lymphocytes and plasma cells. Although this study suggests that RAG is not toxic to sheep when given IV at high doses, additional studies are required to assess the effects of RAG weeks and months after administration.

Our goal to determine whether or not RAG/DMSO administration altered chronic lesions of *M. haemolytica*-induced bronchopneumonia was clear in that the treatment appeared to have no effect. The inability of RAG to structurally alter chronic lung lesions may have been due to several reasons. First, the administration of RAG (33 days after the pneumonia was initiated) when the chronic lesions were already well established may have been too late to affect lung epithelial cell differentiation and proliferation. In future studies, we will determine if RAG can enhance repair of lung lesions when injected intravenously during the initial (acute) stages of bacterial pneumonia. Second, although the timing of RAG administration may have been appropriate, the lung may require more time after administration for lesions to be altered. In this study, lung tissue was collected 17 days after the first RAG inoculation. In studies of RAG in the treatment of acne in skin, months can be required before a noticeable change in lesions becomes evident or measurable.

HPLC analyses of sheep serum and liver extracts from the present study showed that RAG administered by IV

injection was metabolized to a compound that was very similar to RAG. The UV-visible absorption spectrum of both RAG and the new metabolite was the same. Both produced RA on treatment with β -glucuronidase pointing toward the presence of a glucuronic acid moiety in the metabolite (Figures 3 and 4). However, the retention time of the compound during HPLC analysis was different from RAG. The longer retention time of the metabolite in question indicated that it might be a lactone derivative of RAG (Figures 1–3). This has been concluded for several reasons: during column chromatography of pure RAG (as evidenced by a single peak during HPLC) on silica gel, a small fraction of something other than RAG always eluted with a solvent mixture of methanol and dichloromethane much earlier than RAG (unpublished observations in this laboratory). The UV-visible spectra of RAG and the early-eluting fraction were found to be similar. During HPLC, the retention time of the early fraction was found to be much longer (29.7 minutes) than RAG (15.2 minutes), RA (16.8 minutes) retinol (22.4 minutes) and retinyl acetate (27.3 minutes). This change in chromatographic behavior of RAG pointed towards chemical modification of RAG. Since γ -lactones form spontaneously and enzymatically [46], and because glucuronic acid easily undergoes lactonization to glucurono 3,6-lactone, it is possible that the glucuronic acid moiety in RAG underwent lactonization. The formation and identification of retinoyl β -glucurono- γ -lactone during an isolation procedure was reported following incubation of RAG with an anion-exchange resin in the presence of methanol. The retention time of the metabolite of RAG found presently in sheep serum (and in rat serum: unpublished results. David Romans, Arun Barua and James A. Olson) is same as the compound formed from RAG during column chromatography. It was, however, not clear whether this lactone was formed from RAG during the isolation procedure or prior to it. Based on these observations, the metabolite isolated as a major product in rat serum following IP injection of RAG, and noted as a significant RAG metabolite in sheep serum in the present study, has tentatively been identified as retinoyl β -glucurono- γ -lactone (RAGL); the 5-membered (inner ester) ring formed by the glucuronic acid moiety of γ -lactone is known to be a more common arrangement than the 6-membered (inner ester) ring found in δ -lactone [47]. HPLC analyses of serum and liver extracts performed 3 to 5 days after the fourth and last RAG administration showed that RAG and RA had already returned to normal/undetectable levels, while the (RAGL) peak at 29.7 minutes was present only in extracted serum and livers from RAG/DMSO-treated lambs. It is possible that the lingering glucuronolactone was formed as a byproduct in serum resulting from RAG overload. And, whether or not the seemingly slow clearance of the retinoyl β -glucuronolactone from blood is due to a lack of affinity for cellular RA binding protein (CRABP) or nuclear receptors of RA (RARs), like RAG [48], or due to it merely being an atypical, lingering byproduct to be expected in the aftermath of such mega-dosing, is unknown. Regardless, the retinoyl β -glucuronolactone (RAGL) is not being cleared or metabolized as quickly as one might expect with RA (within 6 to 8 hours) or RAG (by

24 hours) in rats, mice or humans. However, inter-species differences with respect to retinoid clearance or metabolism are important to note, i.e. NMRI mice and Wistar rats were shown to be very different in that serum levels of orally administered 9-*cis*-retinoyl β -glucuronide were elevated in the mice far and above that seen in the rats 1 hour after each had received an equimolar dose (210 μ mol/kg animal body weight) of the retinoid. Further, although RA exposure has been shown to promote surfactant production in fetal rats and to promote alveolization in neonatal rats, RA given to late gestation preterm sheep (10–20 mg/kg or 33.3–66.6 μ mol/kg animal body weight) did not appear to accelerate structural or functional maturation of the fetal sheep lung [12].

Besides their potential use in the therapy of respiratory diseases, retinoids are already well used in dermatology and oncology. Topically applied RAG is very effective in treating moderate to moderately severe acne in humans. Furthermore, RA plays a central role in the present therapy for acute promyelocytic leukemia (APL) [49], and is also beneficial in the treatment of neuroblastoma [50], head-and-neck-tumors [51], multiple myeloma, lung or breast cancer [52]. But, since RA brings about its own metabolism by inducing CRABPs and Cytochrome P-450 (CYP 450) enzymes after repeated dosing, thereby limiting its own clinical value, and since RAG lacks binding affinity for CRABP (and therefore cannot be transported to the endoplasmic reticulum to be oxidized by the CYP 450 enzyme system, like RA), RAG appears to be the retinoid most likely to succeed in cases where RA has already been demonstrated to become less effective with prolonged administration. Since nearly twenty five percent of RA-treated APL patients develop toxic 'retinoic acid syndrome', which can be fatal [53,54], an alternative to RA in such treatments is very much needed. In clinical situations, where mode of retinoid delivery is a concern, and since the use of DMSO as a vehicle for drug delivery to humans is not approved by the FDA, other solvents (in addition to aqueous formulations using HP β CD) are currently being sought out, such as Soluphor P (2-pyrrolidone), Lutrol E (PEG) and Solutol HS 15 (PEG hydroxystearate), which are approved for human use [55].

CONCLUSIONS

Highly concentrated, repeated doses of RAG can be given IV to lambs/sheep without overt alterations in behavior, gross lesions, or microscopic lesions in liver and lung. Several days after RAG injections, a lactone derivative develops in the serum and liver of lambs. Multiple high doses of RAG do not resolve established lesions resultant of chronic bacterial bronchopneumonia.

Acknowledgements

We greatly appreciate the work of Calvin Patten Jr, Laboratory Animal Resources and Margie Carter, Iowa State University. We are grateful to Dr. James Allen Olson for his life-long contributions to the field of biochemistry in general, and to the field of vitamin A re-

search specifically; his friendship, guidance and insight will be greatly missed.

REFERENCES:

- Jones TC, Hunt RD, King NW: Veterinary Pathology. Lippincott Williams & Wilkins. 6th ed, 1997; 781
- Barua AB, Furr HC. Properties of Retinoids. Structure, Handling and Preparation (review). Molecular Biotechnology, 1998; 10: 167-182
- Boisvieux-Ulrich E, Le Pechon-Vallee C, Million K et al: Differential effects of several retinoid receptor-selective ligands on squamous differentiation and apoptosis in airway epithelial cells. Cell Tissue Res, 2000; 300: 67-81
- Chytil F: The lungs and vitamin A. Am J Physiol, 1992; 262: L517-527
- Yoon JH, Gray K, Guzman J et al: Regulation of the secretory phenotype of human airway epithelium by retinoic acid, tri-iodothyronine and extracellular matrix. Am J Respir Cell Mol Bio, 1997; 16: 724-731
- Daly TH, Weston WL: Retinoid effects on fibroblast proliferation and collagen synthesis in vitro and on fibrotic disease in vivo. J Am Acad Dermatol, 1986; 15: 900-902
- Massaro GD, Massaro DL: Postnatal treatment with retinoic acid increases the number of pulmonary alveoli in rats. Am J Physiol, 1996; 270(2 pt 1): L305-310
- Massaro GD, Massaro D: Retinoic acid treatment abrogates elastase-induced pulmonary emphysema in rats. Nat Med, 1997; 3: 675-677
- Chytil F: Retinoids in lung development. FASEB J, 1996; 10: 986-992
- Massaro GD, Massaro D: Retinoic acid treatment partially rescues failed septation in rats and in mice. Am J Physiol Lung Cell Mol Physiol, 2000; 278(5): L955-L960
- Kaza AK, Kron LK, Kern JA et al: Retinoic acid enhances lung growth after pneumonectomy. Ann Thorac Surg, 2001; 71: 1645-1650
- Baybutt RC, Hu L, Molteni A: Vitamin A deficiency injures lung and liver parenchyma and impairs function of rat type II pneumocytes. J Nutr, 2000; 130: 1159-1165
- Baybutt RC, Molteni A: Dietary β -carotene protects lung and liver parenchyma of rats treated with monocrotaline. Toxicology, 1999; 137: 69-80
- Barua AB, Duitsman PK, Kostic D et al: Reduction of serum retinoid levels following a single oral dose of all-trans retinoic acid in humans. Internat J Vit Nutr Res, 1997; 67: 423-426
- Gallup JM, Barua AB, Furr HC, Olson JA: Effects of retinoyl β -glucuronide and N-retinoyl amines on the differentiation of HL-60 cells in vitro. Proc Soc Exp Biol Med, 1987; 186: 269-274
- Zile MH, Cullum ME, Simpson RU et al: Induction of differentiation of human promyelocytic leukemia cell line HL-60 by retinoyl glucuronide, a biologically active metabolite of vitamin A. Proc Natl Acad Sci USA, 1987; 84: 2208-2219
- Formelli F, Barua AB, Olson JA: Bioactivities of N-(4-hydroxyphenyl) retinamide and retinoyl β -glucuronide. FASEB J, 1996; 10: 1014-1024
- Barua AB: Retinoyl β -glucuronide: a biologically active form of vitamin A. Nutr Rev 1997; 55(7): 259-267
- Sidell N, Sawatsri S, Connor MJ et al: Pharmacokinetics of chronically administered all-trans-retinoyl- β -glucuronide in mice. Biochim Biophys Acta, 2000; 1502(2): 264-272
- Nau H, Elmazar MMA, Ruhl R et al: All-trans-retinoyl- β -glucuronide is a potent teratogen in the mouse because of extensive metabolism to all-trans-retinoic acid. Teratology, 1996; 54: 150-156
- Lin H-S, Barua AB, Olson JA et al: Pharmacokinetic Study of All-trans-Retinoyl- β -D-Glucuronide in Sprague-Dawley Rats After Single and Multiple Intravenous Administration(s). J Pharm Sci, 2001; 90: 2023-2031
- Gunning DB, Barua AB, Olson JA: Comparative teratogenicity and metabolism of all-trans retinoic acid, all-trans retinoyl β -glucose, and all-trans retinoyl β -glucuronide in pregnant Sprague-Dawley rats. Teratology, 1993; 47: 29-36
- Wadler S, Schwartz EL, Anderson P et al: Preliminary phase II clinical and pharmacokinetic study of 9-cis retinoic acid in advanced cervical cancer. New York Gynecologic Oncology Group. Cancer J Sci Am, 1999; 5: 165-170
- Swaminathan N, Lopez-Berestein G, Rudikoff S: Assessment of all-trans retinoic acid (ATRA) efficacy as a single agent in primary lymphoid neoplasia. Med Oncol, 1999; 16: 119-128
- Gunning DB, Barua AB, Lloyd R, Olson JA: Retinoyl β -glucuronide: a nontoxic retinoid for the topical treatment of acne. J Dermatol Treat, 1994; 5: 181-185
- Becker B, Barua AB, Olson JA: All-trans-retinoyl β -glucuronide: new procedure for chemical synthesis and its metabolism in vitamin A-deficient rats. Biochem J, 1996; 314: 249-252
- Brogden KA, Ackermann MR, Debey MD: Purified lipopolysaccharide-associated protein from Pasteurella haemolytica induces pulmonary inflammation in calves and sheep. Infect Immun, 1995; 63: 3595-3599
- Lee HY, Kehrl ME Jr, Brogden KA et al: Influence of β_2 -integrin adhesion molecule expression and pulmonary infection with Pasteurella haemolytica on cytokine gene expression in cattle. Infect Immun, 2000; 68: 4274-4281
- Barua AB, Olson JA: Reversed-phase gradient high-performance liquid chromatographic procedure for simultaneous analysis of very polar to nonpolar retinoids, carotenoids and tocopherols in animal and plant samples. J Chromatogr B Biomed Sci Appl, 1998; 707: 69-79
- Delvin E, Gianetto R: The purification of lysosomal rat liver β -glucuronidase. Biochem Biophys Acta, 1970; 220: 93-100
- Barua AB, Olson JA: Retinoyl β -glucuronide: an endogenous compound of human blood. Am J Clin Nutr, 1986; 43: 481-485
- Ramirez-Romero R, Brogden KA, Gallup JM et al: Mast cell density and substance P-like immunoreactivity during the initiation and progression of lung lesions in ovine Mannheimia (Pasteurella) haemolytica pneumonia. Microb Pathog, 2001; 30(6): 325-335
- Feiser I, Feiser M: Gamma Lactones do Form Spontaneously. Advancd Organic Chemistry. 1961; Reinhold, New York, p. 574.
- Lippel K, Olson JA. Origin of some derivatives of retinoic acid found in rat bile. J Lipid Res, 1968; 9: 580-586
- Iino N, Yoshida K: Chromatography of β -glucuronidase from bovine liver. A study of the enzyme binding sites of prepared adsorbents. Chem Pharm Bull, 1992; 40(7): 1852-1859
- Perdigon G, Medici M, Cecilia M et al: Significance of the presence of bovine milk β -glucuronidase in mastitis detection. J Dairy Sci, 1986; 69(1): 27-31
- Rethinaswamy A, Yang CH, Srivastava PN: Purification and characterization of β -glucuronidase from seminal plasma and its role in fertilization. Mol Reprod Dev, 1994; 38(4): 404-409
- Healy PJ: Lysosomal hydrolase activity in leukocytes from cattle, sheep, goats, horses and pigs. Res Vet Sci, 1982; 33(3): 275-279
- Dean RT: Rabbit β -glucuronidase. Purification and properties, and the existence of multiple forms. Biochem J, 1974; 138: 395-405
- Barua AB, Duitsman P, Peabody R, Olson JA: Metabolism of orally administered retinoyl β -glucuronide in rats with different vitamin A status. FASEB J, 1996; 10: A525
- Barua AB, Gunning DB, Olson JA: Metabolism *in vivo* of all-trans-[11- 3 H] retinoic acid after an oral dose in rats. Biochem J, 1991; 277: 527-531
- Dunagin PE, Jr, Meadows EH et al: Retinoyl β -glucuronic acid: A major metabolite of Vitamine A in rat bile. Science, 1965; 148: 86-87
- Zile MH, Inhorn RC, DeLuca HF: Metabolism in vivo of all-trans-retinoic acid. Biosynthesis of 13-cis-retinoic acid and all-trans- and 13-cis-retinoyl glucuronides in the intestinal mucosa of the rat. J Biol Chem, 1982; 257: 3544-3550
- McCormick AM, Kroll KD, Napoli J: 13-cis-retinoic acid metabolism in vivo. Biochemistry, 1983; 22: 3933-3940
- Cotran RS, Kumar V, Collins T:(1999) Robbins Pathologic Basis of Disease. 6th ed. WB Saunders Company, 1999; 441
- Smith EL, Hill RL, Lehman IR et al: Principles of Biochemistry: General Aspects. 7th ed. New York: McGraw-Hill Book Company, 1983; 93
- Hansen LA, Sigman CC, Andreola F et al: Retinoids in chemoprevention and differentiation therapy. Carcinogenesis, 2000; 21: 1271-1279

48. Sani BP, Barua AB, Hill DL et al: Retinoyl β -glucuronide: lack of binding to receptor proteins of retinoic acid as related to biological activity. *Biochem Pharmacol*, 1992; 43: 919-922
49. Huang ME, Ye YC, Chen SR et al: Use of all-trans retinoic acid in the treatment of acute promyelocytic leukemia. *Blood*, 1988; 72: 567-572
50. Matthay KK, Villablanca JG, Seeger RC et al: Treatment of high-risk neuroblastoma with intensive chemotherapy, radiotherapy, autologous bone marrow transplantation, and 13-cis-retinoic acid. *New Engl J Med*, 1999; 341: 1165-1173
51. Voravud N, Lippman SM, Weber RS et al: Phase II trial of 13-cis-retinoic acid plus interferon-alpha in recurrent head and neck cancer. *Invest New Drugs*, 1993; 11: 57-60
52. Zhang XK, Liu Y, Lee MO: Retinoid receptors in human lung cancer and breast cancer. *Mutat Res*, 1996; 350: 267-277
53. Chen Z, Wang ZY, Chen SJ: Acute promyelocytic leukemia: Cellular and molecular basis of differentiation and apoptosis. *Pharmacol Ther*, 1997; 76: 141-149
54. Gillis JC, Goa KL: Tretinoin A review of its pharmacodynamic and pharmacokinetic properties and use in the management of acute promyelocytic leukaemia. *Drugs*, 1995; 50: 897-923
55. Alternative injection vehicles approved for use in humans; via Dr. Klaus Kraemer, Scientific Affairs, Marketing Nutraceuticals, BASF Aktiengesellschaft, MEM/FN - D 205, 67056 Ludwigshafen, Germany

Index Copernicus

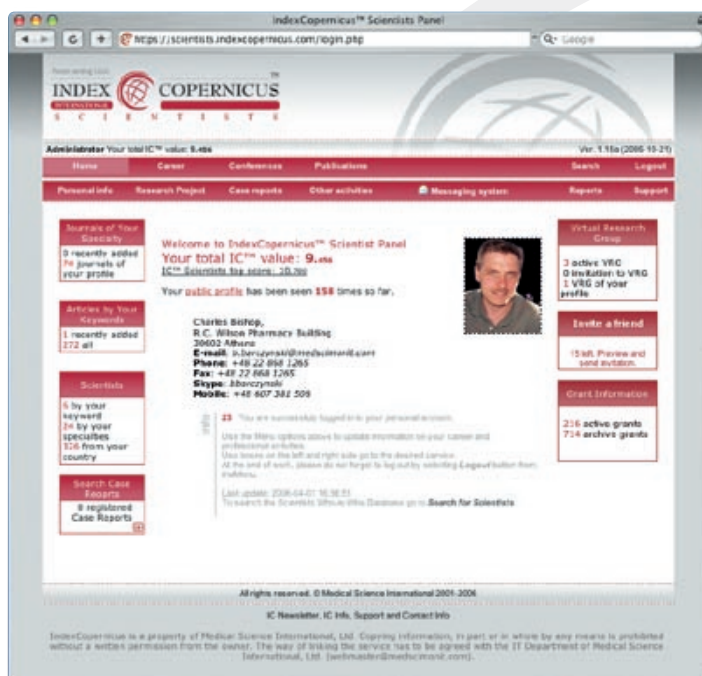Global Scientific Information Systems
for Scientists by Scientists



TM

INDEX
COPERNICUS
INTERNATIONAL

www.IndexCopernicus.com



EVALUATION & BENCHMARKING

PROFILED INFORMATION

NETWORKING & COOPERATION

VIRTUAL RESEARCH GROUPS

GRANTS

PATENTS

CLINICAL TRIALS

JOBS

STRATEGIC & FINANCIAL DECISIONS

Index Copernicus integrates

IC Scientists

Effective search tool for collaborators worldwide. Provides easy global networking for scientists. C.V.'s and dossiers on selected scientists available. Increase your professional visibility.

IC Virtual Research Groups [VRG]

Web-based complete research environment which enables researchers to work on one project from distant locations. VRG provides:

- ⊗ customizable and individually self-tailored electronic research protocols and data capture tools,
- ⊗ statistical analysis and report creation tools,
- ⊗ profiled information on literature, publications, grants and patents related to the research project,
- ⊗ administration tools.

IC Journal Master List

Scientific literature database, including abstracts, full text, and journal ranking. Instructions for authors available from selected journals.

IC Patents

Provides information on patent registration process, patent offices and other legal issues. Provides links to companies that may want to license or purchase a patent.

IC Conferences

Effective search tool for worldwide medical conferences and local meetings.

IC Grant Awareness

Need grant assistance? Step-by-step information on how to apply for a grant. Provides a list of grant institutions and their requirements.

IC Lab & Clinical Trial Register

Provides list of on-going laboratory or clinical trials, including research summaries and calls for co-investigators.