

# Reduction of Pulmonary Mast Cells in Areas of Acute Inflammation in Calves with *Mannheimia (Pasteurella) haemolytica* Pneumonia

R. Ramírez-Romero, K. A. Brogden\*, J. M. Gallup, R. A. F. Dixon† and M. R. Ackermann

Department of Veterinary Pathology, College of Veterinary Medicine, Iowa State University, Ames, Iowa 50011–1250, \*National Animal Disease Center, Agricultural Research Service, United States Department of Agriculture, Ames, Iowa 50010 and †Texas Biotechnology Corporation, 7000 Fannin, Suite 1920, Houston, Texas 77030, USA

## Summary

Mast cells in the left cranial pulmonary lobe of colostrum-deprived neonatal calves were quantified 2 and 6 h after intrabronchial inoculation with *Mannheimia (Pasteurella) haemolytica* A1. The mast cells were detected (1) immunohistochemically with a mouse anti-human mast cell tryptase monoclonal antibody, and (2) by metachromatic staining with low pH toluidine blue. A greater number of mast cells was demonstrated by the second method than by the first. At 6 h after inoculation, but not at 2 h, the number of mast cells was significantly reduced at the site of the main lesions. Treatment of calves with a sialyl Lewis x mimetic (TBC1269) did not appreciably affect the results at 6 h.

© 2000 Harcourt Publishers Ltd

## Introduction

Apart from their role in the IgE-mediated immune response, the relevance of mast cells in non-specific pulmonary defence mechanisms is being recognized increasingly (Abraham *et al.*, 1997). In the respiratory tract, mast cells are essential for bacterial clearance (Malaviya *et al.*, 1996). Furthermore, mast cells produce an array of cytokines and vasoactive compounds that mediate the acute inflammatory response (Malaviya *et al.*, 1996; Abraham *et al.*, 1997; Metcalfe *et al.*, 1997).

*Pasteurella haemolytica* A1, the bacterium most frequently isolated from natural cases of pneumonic pasteurellosis in cattle (Whiteley *et al.*, 1992), has recently been reclassified as *Mannheimia haemolytica* (Angen *et al.* 1999). The pathogenesis of acute

lung injury in bovine pneumonic pasteurellosis is complex and the inflammatory cells and their products have not been fully characterized (Whiteley *et al.*, 1992). Few studies have assessed the role of mast cells in this pneumonic syndrome. However, Adusu *et al.* (1994) reported that mast cells recovered from cattle infected experimentally with *M. haemolytica* release increased amounts of histamine *in vitro*; and *M. haemolytica* leucotoxin and lipopolysaccharide both cause an increase in the spontaneous release of histamine from isolated bovine lung parenchyma (Saban *et al.*, 1997).

The distribution and quantification of mast cells in the bovine lower respiratory tract have been described (Chen *et al.*, 1990; Küther *et al.*, 1998), but there have been no studies on the influence of the acute inflammatory response induced by *M. haemolytica* on the numbers of mast cells in the bovine lung. Kimman *et al.* (1989), however, reported a reduced number of mast cells in the lungs of cattle during the acute phase of natural infection with bovine respiratory syncytial virus. Chevill

Correspondence to: R. Ramírez-Romero Department of Veterinary Pathology, College of Veterinary Medicine, Iowa State University, Ames, Iowa 50011–1250, USA

(1994) suggested that the number of recognizable mast cells decreases during an acute inflammatory response due to their degranulation.

The aim of the present study was to investigate (1) the effect of *M. haemolytica* infection on the number of pulmonary mast cells, the work of Abraham *et al.* (1997) having already suggested that such cells react to gram-negative bacteria, and (2) the effect of a synthetic analogue (TBC1269) of sialyl Lewis (the natural ligand of the selectin family of leucocyte adhesion molecules), which competes with sialylated oligosaccharides, inhibiting the adhesion of selectins *in vitro* (Kogan *et al.*, 1998), and might therefore exert an *in-vivo* effect on mast cells.

## Materials and Methods

### *Animals and Treatments*

Colostrum-deprived, Holstein male calves aged 1–3 days were obtained from Iowa State University Dairy Farms and maintained in isolation rooms in accordance with the methods approved by the American Association for Accreditation of Laboratory Animal Care and the University Animal Care Review Committee. The animals were randomly assigned to five groups. Group 1 (three control animals), which received pyrogen-free saline, were killed at 2 h post-inoculation. Group 2 (four animals) were inoculated with  $10^9$  colony-forming units (cfu) of *M. haemolytica* and killed at 2 h post-inoculation. Group 3 (three control animals), which received pyrogen-free saline, were killed at 6 h. Group 4 (four animals) were inoculated with  $10^9$  cfu of *M. haemolytica* and killed at 6 h post-inoculation. Group 5 (four animals), which received TBC1269 (Texas Biotechnology Corp., Houston, Texas, USA) in pyrogen-free saline (0.9%) intravenously (25 mg/kg) 30 min before and 2 h after inoculation with  $10^9$  cfu of *M. haemolytica*, were killed at 6 h post-inoculation. Euthanasia was carried out with an intravenous overdose of sodium pentobarbital.

### *Intrabronchial Inoculation and Collection of Tissues*

Saline and *M. haemolytica* suspension, in volumes of 5 ml, were deposited in the left cranial bronchi by fibreoptic bronchoscopy as previously described (Brogden *et al.*, 1995; Ackermann *et al.*, 1996). Samples of lung from the animals receiving *M. haemolytica* inocula were collected from the site of the inoculum deposition (site 2) and from two adjacent sites, cranial (site 1) and caudal (site 3) to the lesion. Equivalent samples were collected from

the control animals that had received saline. The samples were fixed in buffered 10% formalin.

### *Histological and Immunohistochemical Examination*

The samples were embedded in paraffin wax, sectioned (4  $\mu$ m) and stained with haematoxylin and eosin (HE), Giemsa, astra blue, toluidine blue or low pH toluidine blue, or immunohistochemically for tryptase. Except for HE, which was employed for evaluation of histological changes, the stains were used for the recognition of mast cells. Low pH toluidine blue and tryptase staining were carried out as described by Chen *et al.* (1990) and Küther *et al.* (1998), respectively.

Immunohistochemical examination was made with a primary monoclonal mouse antibody (anti-human skin mast cell tryptase) recommended for formalin-fixed, paraffin wax-embedded tissue sections (Mast Cell, AA1; Dako, Carpinteria, California, USA). Briefly, the slides were heated in an oven for 30 min at 58°C, dewaxed in xylene and treated with a succession of graded alcohols. Subsequently, they were subjected to an antigen retrieval process which included heating the slides to boiling (*c.* 1.5 min) in citrate buffer (pH 6.0) followed by an extended heating (*c.* 95°C) for 10 min. They were then pre-digested with 0.1% protease XIV (Sigma, St Louis, Missouri, USA) at 37°C for 5 min. The primary antibody was applied at a 1 in 50 dilution and the slides were incubated for 1 h at room temperature. The secondary antibody, affinity-purified biotinylated goat anti-mouse (KPL, Gaithersburg, Maryland, USA), was employed at 1 in 200 dilution and the slides were incubated for 30 min. The procedure included a 30-min treatment with super-sensitive alkaline phosphatase (BioGenex, San Ramon, California, USA), followed by two 30-min applications of Histomark Red (KPL, Gaithersburg, Maryland, USA). All of these steps were carried out in an OptiMax® Plus automated cell staining system (BioGenex). The slides were counterstained with haematoxylin for 20 s, dehydrated through alcohols, cleared in Pro-Par (Anatech Ltd, Battle Creek, Michigan, USA) and “coverslipped”. Negative controls, omitting the primary antibody, were included.

### *Procedure for Counting Mast Cells, and Statistical Analysis*

Mast cells were counted in 20 high-power ( $\times 400$ ) fields (equivalent to *c.* 3.694 mm<sup>2</sup>) and expressed in cells/mm<sup>2</sup>, as described by Chen *et al.* (1990). The fields were randomly selected on each slide

with no premeditated intention to avoid empty spaces except for the lumina of large airways or large blood vessels. A first counting procedure included the three sites (1, 2, and 3) in infected and control animals. There were usually two slides from each site, each slide bearing two lung sections, but only a single section, randomly selected, from each of sites 1–3, was used; the result for each animal was the mean value obtained from the three sites. In a second counting procedure sites 1 and 3 were excluded, mast cells being counted only in site 2; average values were obtained from counting three sections, except in two animals from which only two sections were available.

The data were analysed in a completely random design with the model  $\hat{y}_{ij} = \mu + \tau_i + \varepsilon_{ij}$ . Subsequently, a Tukey's *w* procedure was used for specific comparisons (Steel *et al.*, 1997).

## Results

### Gross Lesions and Histopathology

Macroscopically, all of the animals inoculated with *M. haemolytica* (groups 2, 4 and 5) showed characteristic lesions of pneumonic pasteurellosis, including consolidation with zones of haemorrhage and variable amounts of fibrin on the pleural surface. These lesions ranged from moderate to severe and were always confined to the site of deposition of the inocula. Animals killed at 6 h post-inoculation had the more severe changes. The main lesions, which varied in diameter from 4 to 8 cm, were confined to site 2; the adjacent areas (sites 1 and 3) showed mild congestion and oedema. Control animals (groups 1 and 3) had no lesions. Microscopically, site 2 in the lungs of the infected animals showed a moderate to severe suppurative or fibrinosuppurative bronchopneumonia and extensive areas of alveolar oedema and haemorrhage; these were multifocal, the foci sometimes coalescing. The lesions in the adjacent sites 1 and 3 were characterized by interstitial and alveolar oedema, with neutrophils in the interstitium and bronchioles and adjacent alveolar spaces; these lesions were considered mild and had a diffuse distribution with interspersed areas of normal tissue. The control animals showed mainly normal tissue with some discrete areas of thickening of the alveolar septa due to interstitial oedema. There was no evidence of inflammatory response.

### Mast Cells

The criteria for optimal detection of mast cells were (1) distinctive staining, enabling mast cells to

be recognized at medium ( $\times 100$ ) power, and (2) absence of interfering background. The immunohistochemical procedure for tryptase proved to be the best method for producing distinctive staining, followed by low pH toluidine blue. Mast cells in sections treated immunohistochemically had deeply stained, bright red cytoplasm (Fig. 1B, inset), whereas low pH toluidine blue gave the characteristic metachromatic appearance of mast cell cytoplasm (Fig. 1A and B). When the two procedures were used on replicate sections from randomly selected animals, higher numbers of mast cells were detected ( $P < 0.01$ ) with the low pH toluidine blue stain. The analysis for comparison was a Student's *t*-test, assuming independent samples and unequal variances (Steel *et al.*, 1997). Tryptase staining yielded a result of  $0.507 \pm 0.394$  mast cells/mm<sup>2</sup> (mean  $\pm$  SD;  $n = 8$ ), whereas low pH toluidine blue yielded  $5.210 \pm 2.655$  mast cells/mm<sup>2</sup> (mean  $\pm$  SD;  $n = 8$ ). The latter method was therefore chosen for comparing the different animal groups.

In the comparison made by the first counting procedure (average of values from sites 1–3) analysis of variance (ANOVA) indicated differences between the groups of animals but not at a statistically significant level ( $P > 0.05$ ) (Table 1). However, the comparison made by the second counting procedure (average of values from site 2) revealed highly significant differences between groups ( $P < 0.005$ ). A posterior analysis of the data made with Tukey's *w* procedure (Steel *et al.*, 1997) demonstrated that calves inoculated with *M. haemolytica* and killed 6 h later (Groups 4 and 5) had reduced numbers of mast cells as compared with controls (Groups 1 and 3) ( $P < 0.05$ ). Calves in Group 2, also inoculated with *M. haemolytica* but killed 2 h later, also had reduced numbers of mast cells but the reduction was not statistically significant ( $P > 0.05$ ). Differences were not detected between the infected groups (2, 4 and 5) (Table 2).

## Discussion

The decreased number of mast cells in the lung of calves inoculated with *M. haemolytica* was restricted to the site of the main lesions. This decrease was statistically significant at 6 h post-inoculation but not as early as 2 h. Mast cells were particularly scarce in areas with severe damage, characterized by fibrinopurulent or fibrinohaemorrhagic pneumonic lesions. However, when less-affected areas adjacent to the site of severe lesions were included in the comparisons, the numbers of mast cells were reduced but not to a statistically significant level.

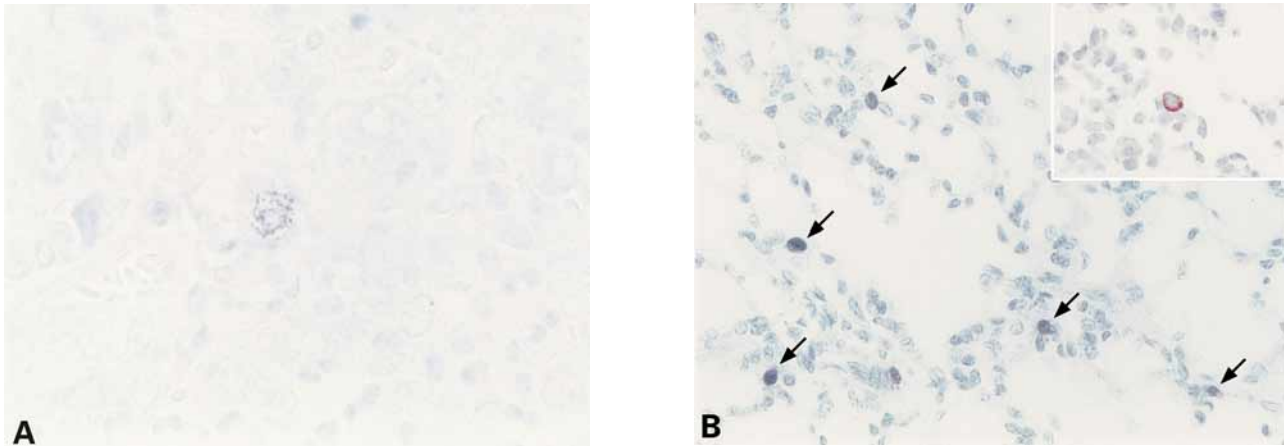


Fig. 1. Sections of lung corresponding to site 2, the site with the main lesion in an animal that received *M. haemolytica* (A) and its equivalent in a control that received saline (B), both killed at 6 h post-inoculation. In picture A, there is a single mast cell, partly degranulated, in an area with extensive consolidation. Low pH toluidine blue.  $\times 240$ . In picture B, there are several mast cells and no tissue damage. Low pH toluidine blue.  $\times 120$ . The inset shows a single tryptase-positive mast cell. Immunolabelling.  $\times 240$ .

**Table 1**  
Numbers of mast cells (means obtained from sites 1–3) in calves of Groups 1–5

Individual calves in 5 Groups	Mean numbers of mast cells/mm <sup>2</sup> in sites 1–3 at				
	2 h after inoculation in calves of Groups		6 h after inoculation in calves of Groups		
	1 (controls; n=3)	2 (infected; n=4)	3 (controls; n=3)	4 (infected; n=4)	5 (infected and TBC1269-treated; n=4)
1	7.57	8.84*	7.12	4.96	4.14
2	6.58	2.25	6.49	4.14	3.66
3	4.60	3.99	5.95	2.25	3.03
4	...	4.78	...	2.52	1.92
Mean $\pm$ SD	6.25 $\dagger$ $\pm$ 1.51	4.96 $\dagger$ $\pm$ 2.79	6.52 $\dagger$ $\pm$ 0.58	3.46 $\dagger$ $\pm$ 1.29	3.18 $\dagger$ $\pm$ 0.95

\* This animal showed the least severe lesions of all infected animals.

$\dagger$  These values were not significantly different from each other (ANOVA;  $P > 0.05$ ).

**Table 2**  
Numbers of mast cells (means obtained from site 2) in calves of Groups 1–5

Individual calves in 5 Groups	Mean numbers of mast cells/mm <sup>2</sup> in site 2 at				
	2 h after inoculation in calves of Groups		6 h after inoculation in calves of Groups		
	1 (controls; n=3)	2 (infected; n=4)	3 (controls; n=3)	4 (infected; n=4)	5 (infected and TBC1269-treated; n=4)
1	8.11	9.06*	7.57	3.24	2.79
2	8.28	1.98	6.49	2.83	3.78
3	5.27	3.80	8.02	3.15	1.89
4	...	4.05	...	1.98	1.35
Mean $\pm$ SD	7.22 <sup>a</sup> $\pm$ 1.69	4.72 <sup>ab</sup> $\pm$ 3.03	7.36 <sup>a</sup> $\pm$ 0.78	2.80 <sup>b</sup> $\pm$ 0.57	2.45 <sup>b</sup> $\pm$ 1.06

\* This animal showed the least severe lesions of all infected animals.

$\dagger$  Values with different superscript letter are different at a significant level (Tukey's *w* test;  $P < 0.05$ ).

This suggests that the disappearance of mast cells due to degranulation during an acute inflammatory response (Cheville, 1994) is intimately related to the intensity of the lesion and the time of exposure. Furthermore, this confirms the relevant role of mast cells during an acute inflammatory response, particularly in the lung.

It has been postulated that mast cells represent one of the most important means of defence in the lung in both innate and immune responses (Abraham *et al.*, 1997). In a mouse model of pneumonia produced by *Klebsiella pneumoniae*, mast cells were necessary for modulating the lung inflammatory response and bacterial clearance (Malaviya *et al.*, 1996); these effects were mainly attributed to the release of tumour necrosis factor- $\alpha$  (TNF- $\alpha$ ) from mast cell granules. Additionally, mast cells contain a vast array of pro-inflammatory cytokines, such as interleukin-1 (IL-1) and interleukin-8 (IL-8) (Abraham *et al.*, 1997; Metcalfe *et al.*, 1997). Increased amounts of these cytokines have been demonstrated in the lungs of cattle with pneumonic pasteurellosis (Yoo *et al.*, 1995; Caswell *et al.*, 1998).

Chen *et al.* (1990) reported that with low pH toluidine blue, formalin and isotonic formalin-acetic acid fixation resulted in similar numbers of stained pulmonary mast cells. The same authors found that the number of mast cells was dramatically lower (*c.* 12 mast cells/mm<sup>2</sup>) in 8-day-old calves than in adult cattle. In the present study *c.* 7 mast cells/mm<sup>2</sup> were recognized in the controls, but the calves were younger than those examined by Chen *et al.*, (1990).

Mast cell proteases are considered to be the most specific markers for mast cells (Metcalfe *et al.*, 1997; Welle, 1997). Tryptase-positive mast cells form the great majority (>95%) of mast cells in the bovine lung (Küther *et al.*, 1998; Jolly *et al.*, 1999). For demonstration of mast cell proteases, Küther *et al.* (1998) reported that the use of Carnoy's fixative was preferable to formalin fixation, but the difference was not statistically significant in the lungs of adult cattle; the authors suggested that mast cells from various tissues exhibited different sensitivity to formalin and that bovine mast cells were relatively formalin-resistant. However, Küther *et al.* (1998) employed a polyclonal rabbit anti-human mast cell tryptase antibody, whereas we used a monoclonal mouse anti-human antibody. Nonetheless, the results in quality of staining were comparable but, as already mentioned, the number of cells demonstrated immunohistochemically was less than that stained by low pH toluidine blue. More recently, Jolly *et al.* (1999) reported that a monoclonal

mouse anti-human skin mast cell tryptase antibody worked well in recognizing tryptase-positive mast cells in the bovine lung; however, as in the present study, higher numbers of mast cells were detected with low pH toluidine blue stain. Jolly *et al.* (1999) suggested that one of the reasons for this discrepancy was the high specificity but lack of sensitivity of this monoclonal antibody; an alternative possibility was that the type of tryptase produced by bovine mast cells was unable to react readily with the monoclonal antibody employed.

Mast cell density and staining properties may be influenced by a number of factors, including age and health. In the rat, mast cells have not been recognized in the fetus (Jeffery, 1998) and are very scarce in the newborn (Wilkes *et al.*, 1992). Mast cells arrive in an immature state of differentiation in the tissues in which they complete their maturation (Metcalfe *et al.*, 1997). Here they first express proteoglycan (heparin); the expression of the proteases occurs at the end of the process in mature mast cells (Welle, 1997). It is possible, therefore, that the numbers of mature mast cells expressing tryptase were low in the present study because of the young age of the calves. Metachromatic staining of immature mast cells may be possible as the result of early expression of a proteoglycan matrix in their granules.

In a model of viral bronchiolitis in rats infected with Sendai virus, increase in the number of mast cells resulted from both a proliferation of pre-existing mast cells and an augmented recruitment of circulating mast cell precursors, but a significant increase in mast cells occurred only after day 14 post-infection (Sorden and Castleman, 1995). Conversely, during acute episodes of naturally occurring bovine respiratory syncytial virus infection, the numbers of pulmonary mast cells decrease (Kimmman *et al.*, 1989); furthermore, the lungs of the virus-infected cattle contained an increased proportion of degranulated mast cells. Our observations were compatible with the results of Kimmman *et al.* (1989).

Since the synthetic compound TBC1269 is a potent inhibitor of selectin-mediated cell adhesion *in vitro* (Kogan *et al.*, 1998), we suspected that reducing the infiltration of neutrophils would have an effect on mast cell degranulation. This notion is supported by the recent work of Befus *et al.* (1999), who demonstrated that neutrophil defensins induce mast cell degranulation. However, the decreased numbers of mast cells in TBC1269-treated animals (Group 5) were not significantly different from those in animals receiving the bacteria alone (Groups 2 and 4). Thus, TBC1269 did not prevent

the initial degranulation of mast cells. Similarly, in a mouse model of mast-cell-dependent inflammation in the skin, degranulation of mast cells was not prevented in mice genetically incapable of producing P- and E-selectins (De Mora *et al.*, 1998).

### Acknowledgments

The authors thank B. Smith for technical assistance, Drs Z. Radi and J. Caverly for the collection of tissues, Dr M. M. Welle for suggestions and comments concerning the immunohistochemical procedure, and Dr S. D. Sorden for advice on the procedure for counting mast cells. This work was supported in part by USDA/NRI Project 970–2654. R. Ramírez-Romero is a graduate student receiving financial support from Universidad Autónoma de Nuevo León and CONACYT, México.

### References

- Abraham, S. N., Thankavel, K. and Malaviya, R. (1997). Mast cells as modulators of host defense in the lung. *Frontiers in Bioscience*, **2**, 78–88.
- Ackermann, M. R., Kehrl, M. E. Jr and Brogden, K.A. (1996). Passage of CD18<sup>-</sup> and CD18<sup>+</sup> bovine neutrophils into pulmonary alveoli during acute pneumonia. *Veterinary Pathology*, **33**, 639–646.
- Aduis, T. E., Conlon, P. D., Shewen, P. E. and Black, W. D. (1994). *Pasteurella haemolytica* leukotoxin induces histamine release from bovine pulmonary mast cells. *Canadian Journal of Veterinary Research*, **58**, 1–5.
- Angen, O., Mutters, R., Caugant, D. A., Olsen, J. E. and Bisgaard, M. (1999). Taxonomic relationships of the [*Pasteurella*] *haemolytica* complex as evaluated by DNA–DNA hybridizations and 16S rRNA sequencing with proposal of *Mannheimia haemolytica* gen. nov., comb. nov., *Mannheimia granulomatis* comb. nov., *Mannheimia glucosida* sp. nov., *Mannheimia ruminalis* sp. nov. and *Mannheimia varigena* sp. nov. *International Journal of Systematic Bacteriology*, **49**, 67–86.
- Befus, A. D., Mowat, C., Gilchrist, M., Hu, J., Solomon, S. and Bateman, A. (1999). Neutrophil defensins induce histamine secretion from mast cells: mechanisms of action. *Journal of Immunology*, **163**, 947–953.
- Brogden, K. A., Ackermann, M. R. and DeBey, B. M. (1995). *Pasteurella haemolytica* lipopolysaccharide associated protein induces pulmonary inflammation after bronchoscopy deposition in calves and sheep. *Infection and Immunity*, **63**, 3595–3599.
- Caswell, J. L., Middleton, D. M., Sorden, S. D. and Gordon, J. R. (1998). Expression of neutrophil chemoattractant interleukin-8 in the lesions of bovine pneumonic pasteurellosis. *Veterinary Pathology*, **35**, 124–131.
- Chen, W., Alley, M. R., Manktelow, B. W. and Slack, P. (1990). Mast cells in the bovine lower respiratory tract: morphology, density and distribution. *British Veterinary Journal*, **146**, 425–436.
- Cheville, N. F. (1994). *Ultrastructural Pathology. An Introduction to Interpretation*, Iowa State University, Ames, IA.
- De Mora, F., Williams, C. M. M., Frenette, P. S., Wagner, D. D., Hynes, R. O. and Galli, S. J. (1998). P- and E-selectins are required for the leukocyte recruitment, but not the tissue swelling, associated with IgE- and mast cell-dependent inflammation in mouse skin. *Laboratory Investigation*, **78**, 497–505.
- Jeffery, P. K. (1998). The development of large and small airways. *American Journal of Respiratory and Critical Care Medicine*, **157**, S174–S180.
- Jolly, S., Coignoul, F., Gabriel, A. and Desmecht, D. (1999). Detection of tryptase in bovine mast cells: Comparison of enzyme- and immuno-histochemistry. *Journal of Comparative Pathology*, **120**, 269–279.
- Kimman, T. G., Terpstra, G. K., Daha, M. R. and Westenbrink, F. (1989). Pathogenesis of naturally acquired bovine respiratory syncytial virus infection in calves: evidence for the involvement of complement and mast cell mediators. *American Journal of Veterinary Research*, **50**, 694–700.
- Kogan, T. P., Dupré, B., Bui, H., McAbbe, K. L., Kassir, J. M., Scott, I. L., Hu, X., Vanderslice, P., Beck, P. J. and Dixon, R. A. F. (1998). Novel synthetic inhibitors of selectin-mediated cell adhesion: synthesis of 1,6-Bis[3-(3-carboxymethylphenyl)-4-(2- $\alpha$ -D-mannopyranosyloxy)phenyl] hexane (TBC1269). *Journal of Medicinal Chemistry*, **41**, 1099–1111.
- Küther, K., Audigé, L., Kube, P. and Welle, M. (1998). Bovine mast cells: distribution, density, heterogeneity, and influence of fixation techniques. *Cell Tissue Research*, **293**, 111–119.
- Malaviya, R., Ikeda, T., Ross, E. and Abraham, S. N. (1996). Mast cell modulation of neutrophil influx and bacterial clearance at sites of infection through TNF- $\alpha$ . *Nature*, **381**, 77–80.
- Metcalfe, D. D., Baram, D. and Mekori, Y. A. (1997). Mast cells. *Physiological Reviews*, **77**, 1033–1079.
- Saban, R., Broadstone, R. V., Haak-Frendscho, M., Skoyen, S., Fialkowski, J., Maheswaran, S. K., Bjorling, D. E. and Czuprynski, C. (1997). Effects of *Pasteurella haemolytica* leukotoxin and lipopolysaccharide on histamine, prostanoid, and leukotriene release by bovine lung parenchyma in vitro. *American Journal of Veterinary Research*, **58**, 1227–1231.
- Sorden, S. D. and Castleman, W. L. (1995). Virus-induced increases in bronchiolar mast cells in Brown Norway rats associated with local mast cell proliferation and increases in blood mast cell precursors. *Laboratory Investigation*, **73**, 197–204.
- Steel, R. G. D., Torrie, J. H. and Dickey, D. A. (1997). *Principles and Procedures of Statistics: a Biometrical Approach*, 3rd Edit, McGraw-Hill, New York.
- Welle, M. (1997). Development, significance, and heterogeneity of mast cells with particular regard to the mast cell-specific proteases chymase and tryptase. *Journal of Leukocyte Biology*, **61**, 233–245.
- Whiteley, L. O., Maheswaran, S. K., Weiss, D. J. and Ames, T. R. (1992). *Pasteurella haemolytica* A1 and bovine respiratory disease: pathogenesis. *Journal of Veterinary Internal Medicine*, **6**, 11–22.

Wilkes, L. K., McMenamin, C. and Holt, P. G. (1992). Postnatal maturation of mast cell subpopulations in the rat respiratory tract. *Immunology*, **75**, 535–541.

Yoo, H. S., Maheswaran, S. K., Srinand, S., Ames, T. R. and Suresh, M. (1995). Increased tumor necrosis factor-alpha and interleukin-1 beta expression in the

lungs of calves with experimental pneumonic pasteurellosis. *Veterinary Immunology and Immunopathology*, **49**, 15–28.

[ *Received, 19 April, 1999,*  
*Accepted, 20 December, 1999* ]