

10-2020

## Hypercalcemia of malignancy associated with exocrine pancreatic adenocarcinoma in a dog

Chad M. Johannes

*Iowa State University*, cmj15@iastate.edu

Ellen R. E. Heinrich

*Iowa State University*

Margaret L. Musser

*Iowa State University*, mmusser@iastate.edu

Claire B. Andreasen

*Iowa State University*, candreas@iastate.edu

Follow this and additional works at: [https://lib.dr.iastate.edu/vpath\\_pubs](https://lib.dr.iastate.edu/vpath_pubs)



Part of the [Veterinary Pathology and Pathobiology Commons](#)

The complete bibliographic information for this item can be found at [https://lib.dr.iastate.edu/vpath\\_pubs/115](https://lib.dr.iastate.edu/vpath_pubs/115). For information on how to cite this item, please visit <http://lib.dr.iastate.edu/howtocite.html>.

---

This Article is brought to you for free and open access by the Veterinary Pathology at Iowa State University Digital Repository. It has been accepted for inclusion in Veterinary Pathology Publications and Papers by an authorized administrator of Iowa State University Digital Repository. For more information, please contact [digirep@iastate.edu](mailto:digirep@iastate.edu).

---

# Hypercalcemia of malignancy associated with exocrine pancreatic adenocarcinoma in a dog

## Abstract

A 10.5-year-old, male, neutered Samoyed was presented to the Iowa State University Lloyd Veterinary Medical Center with history (including prior surgical biopsy), non-specific acute clinical signs and clinicopathology changes most consistent with pancreatitis. Marked hypercalcemia developed within a short span of time, raising clinical concerns for neoplasia. Diagnostic imaging and fine-needle aspirate cytology were consistent with pancreatitis. Marked elevation in parathyroid hormone-related protein with low parathyroid hormone further supported the diagnosis of underlying neoplasia. The dog's clinical status declined despite aggressive medical supportive therapy. Humane euthanasia was elected. Postmortem examination revealed an extensive pancreatic neoplasm confirmed as exocrine pancreatic adenocarcinoma with diffuse intra-abdominal metastases. Acute kidney injury most likely resulted from the severe pancreatic inflammation (pancreatitis) and hypercalcemia of malignancy caused by the exocrine pancreatic adenocarcinoma. This is the first reported case of hypercalcemia of malignancy associated with exocrine pancreatic adenocarcinoma in a dog.

## Keywords

exocrine pancreatic adenocarcinoma, hypercalcemia of malignancy, paraneoplastic

## Disciplines

Veterinary Pathology and Pathobiology

## Comments

This is the published version of the following article: Johannes, Chad M., Ellen RE Heinrich, Margaret L. Musser, and Claire B. Andreasen. "Hypercalcemia of malignancy associated with exocrine pancreatic adenocarcinoma in a dog." *Veterinary Record Case Reports* 8, no. 4 (2020): e001190. DOI: [10.1136/vetreccr-2020-001190](https://doi.org/10.1136/vetreccr-2020-001190). Posted with permission.

## Creative Commons License




This work is licensed under a [Creative Commons Attribution-Noncommercial 4.0 License](https://creativecommons.org/licenses/by-nc/4.0/)



OPEN ACCESS

COMPANION OR PET ANIMALS

# Hypercalcemia of malignancy associated with exocrine pancreatic adenocarcinoma in a dog

 Chad M Johannes ,<sup>1</sup> Ellen R E Heinrich,<sup>1</sup> Margaret L Musser,<sup>1</sup> Claire B Andreasen<sup>2</sup>

<sup>1</sup>Veterinary Clinical Sciences, Iowa State University College of Veterinary Medicine, Ames, Iowa, USA

<sup>2</sup>Department of Veterinary Pathology, Iowa State University College of Veterinary Medicine, Ames, Iowa, USA

## Correspondence to

Dr Chad M Johannes; cmj15@iastate.edu

Received 21 May 2020

Revised 3 August 2020

Accepted 24 September 2020

## SUMMARY

A 10.5-year-old, male, neutered Samoyed was presented to the Iowa State University Lloyd Veterinary Medical Center with history (including prior surgical biopsy), non-specific acute clinical signs and clinicopathology changes most consistent with pancreatitis. Marked hypercalcemia developed within a short span of time, raising clinical concerns for neoplasia. Diagnostic imaging and fine-needle aspirate cytology were consistent with pancreatitis. Marked elevation in parathyroid hormone-related protein with low parathyroid hormone further supported the diagnosis of underlying neoplasia. The dog's clinical status declined despite aggressive medical supportive therapy. Humane euthanasia was elected. Postmortem examination revealed an extensive pancreatic neoplasm confirmed as exocrine pancreatic adenocarcinoma with diffuse intra-abdominal metastases. Acute kidney injury most likely resulted from the severe pancreatic inflammation (pancreatitis) and hypercalcemia of malignancy caused by the exocrine pancreatic adenocarcinoma. This is the first reported case of hypercalcemia of malignancy associated with exocrine pancreatic adenocarcinoma in a dog.

## BACKGROUND

Hypercalcemia of malignancy (HM) in dogs is most commonly associated with lymphoma or apocrine gland anal sac adenocarcinoma (AGASAC) and usually results from production of parathyroid hormone-related protein (PTHrP) by the neoplastic cells.<sup>1,2</sup> A number of other carcinomas (squamous cell, thyroid, mammary, pulmonary, etc) have also been less commonly identified as causes of HM.<sup>2,3</sup> This report highlights the first case of exocrine pancreatic adenocarcinoma resulting in HM in a dog. Hypercalcemia of malignancy resulting from increased production of PTHrP is reported in human exocrine pancreatic adenocarcinoma, particularly in those cases with adenosquamous differentiation.<sup>4</sup> This case also highlights the key clinical point that pancreatic adenocarcinoma can mimic pancreatitis on the basis of presentation, physical examination findings, and clinicopathology and diagnostic imaging results. These similarities are likely related to the intense pancreatic inflammation occurring secondary to the neoplastic process.<sup>5,6</sup> Although rarely reported in dogs, exocrine pancreatic adenocarcinoma should be considered as a differential diagnosis in cases of suspected pancreatitis not responsive to typical supportive therapies or in cases with hypercalcemia and pertinent pancreatic clinical

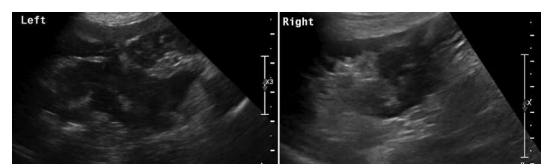
signs and/or changes on clinicopathology or diagnostic imaging.

## CASE PRESENTATION

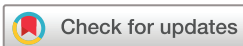A 10.5-year-old, male, neutered Samoyed was presented to the Iowa State University Lloyd Veterinary Medical Center for evaluation of progressive, intermittent vomiting, hyporexia and lethargy. On initial physical examination, the dog was quiet, alert and responsive with a body weight of 24.3 kg and body condition score of 5/9. Additional findings were elevated body temperature (39.8°C); heart rate 108 beats/min with regular rhythm and strong, synchronous femoral pulses; respiratory rate 36 breaths/min, eupneic with clear lung fields; and mucous membranes pink and slightly tacky. Clinical dehydration status was estimated at <5 per cent. The dog's abdomen was mildly distended, tense and painful on palpation with no organomegaly or distinct masses palpable. Urine dribbling was noted. Peripheral lymph nodes were small, soft and symmetrical. Rectal examination was unremarkable with no masses or lymphadenomegaly. Fundic examination was unremarkable.

Evaluation by the primary care veterinarian 3 days earlier had revealed elevated body temperature (39.4°C) with a slightly distended and tense abdomen. Diagnostics performed at that time showed neutrophilia ( $15.0 \times 10^3/\mu\text{L}$ , reference interval (RI) 2.95–11.64) and mildly elevated canine pancreatic lipase immunoreactivity (cPLI, 235  $\mu\text{g/L}$ , RI  $\leq 200$ ). Baseline cortisol (1.6  $\mu\text{g/dL}$ , RI 1.0–5.0) and total calcium (9.1  $\text{mg/dL}$ , RI 7.9–12.0) were within reference interval. Diagnostic imaging had no significant findings in two-view thoracic radiographs; however, abdominal radiographs had loss of serosal detail with a mottled appearance in the cranioventral abdomen.

Previous history included exploratory coeliotomy for duodenal foreign body removal at 2 years of age, during which gross changes were observed in the pancreas, a biopsy taken,



**Figure 1** Diffusely enlarged left (A) and right (B) pancreatic lobes exhibit hypochoic, mildly heterogeneous parenchyma with undulant margins and surrounding hyperechoic mesenteric fat.



© British Veterinary Association 2020. Re-use permitted under CC BY-NC. No commercial re-use. Published by BMJ.

**To cite:** Johannes CM, Heinrich ERE, Musser ML, et al. *Vet Rec Case Rep* Published Online First: [please include Day Month Year]. doi:10.1136/vetreccr-2020-001190

and histopathology-confirmed necrosuppurative pancreatitis. Subsequent clinical episodes consistent with pancreatitis were managed with supportive medical therapy (antiemetics) and diet. One year prior to presentation for the current condition, spontaneous pneumothorax was diagnosed. A right middle lung lobe lobectomy was performed with no concerning changes noted on histopathology. No further respiratory clinical signs had been observed.

## INVESTIGATIONS

Complete blood count (CBC) at presentation revealed leucocytosis (29.52/ $\mu\text{L}$ , RI 6.0–17.0) composed of a neutrophilia (26.86/ $\mu\text{L}$ , RI 3.0–11.4) and mild left shift (886 band neutrophils/ $\mu\text{L}$ , RI 0–300) with slight toxic granulation; and mild normocytic, normochromic anaemia (haematocrit 29.6 per cent, RI 37–55). Serum biochemistry profile indicated increased total calcium (13.4 mg/dL, RI 9.7–11.3). Ionised calcium was elevated (1.71 mmol/L, RI 1.25–1.45). Urinalysis showed isosthenuria (urine specific gravity 1.009) with 1+ protein; urine protein:creatinine ratio was 1.99. Canine trypsin-like immunoreactivity (cTLI) was elevated (>50  $\mu\text{g/L}$ , RI 5.7–45.2), as was cPLI (272  $\mu\text{g/L}$ , RI  $\leq 200$   $\mu\text{g/L}$ ); serum folate and cobalamin were within reference interval. ACTH stimulation test indicated elevated pre-cortisol level (8.84  $\mu\text{g/dL}$ , RI 1.0–5.0) with post-cortisol within reference interval (18.5  $\mu\text{g/dL}$ , RI 5.5–20.0).

Thoracic radiographs (three-view) revealed moderate sternal lymphadenomegaly suspected to be secondary to abdominal disease; no visible changes consistent with metastatic neoplasia were observed. The entire pancreas was markedly enlarged and hypoechoic on abdominal ultrasound, extending caudally near the level of the urinary bladder (figure 1). The surrounding adipose was heterogeneous and hyperechoic; a moderate amount of hypoechoic free abdominal fluid was present. An enlarged, lobular pancreatic lymph node was noted near the left limb of the pancreas. Several small, hyperechoic nodules were noted within the spleen near the mesenteric margin. Due to changes observed on ultrasound, fine-needle aspirates were obtained from the pancreas and spleen; a sample of free peritoneal fluid was obtained for analysis. Although no changes were noted on ultrasound evaluation of the liver, fine-needle aspirates were performed to exclude lymphoma as a cause of HM. The enlarged pancreatic lymph node was not accessible for aspiration. Pancreatic cytology revealed neutrophilic inflammation with pyogranulomatous steatitis, necrosis, and typical and low numbers of atypical (high nuclear to cytoplasmic ratio) pancreatic cells. Differentials for the atypical pancreatic cells were morphology changes due to inflammation and necrosis or possible neoplasia. Splenic cytology indicated mild hemosiderin and extramedullary hematopoiesis. Liver cytology indicated mild bile retention and blood-associated neutrophilia. Peritoneal fluid analysis was consistent with a neutrophilic inflammatory exudate. Sternal bone marrow aspirate was performed and no evidence of lymphoma or other neoplasia was identified. A hypercalcemia panel was submitted to the Michigan State University Veterinary Diagnostic Laboratory.

## DIFFERENTIAL DIAGNOSIS

Based on the clinical history and presentation, diagnostic imaging, inflammatory changes noted on CBC and aspirates of the pancreas and abdominal fluid, pancreatitis was the initial primary differential diagnosis. However, the newly identified hypercalcemia was not expected with acute pancreatitis as this

condition is most commonly associated with hypocalcemia.<sup>7</sup> Given the extensive pancreatic changes noted on abdominal ultrasound along with hypercalcemia, further consideration was given to pancreatic neoplasia (lymphoma, adenocarcinoma, insulinoma). The dog was normoglycemic and cytology of the pancreas and abdominal fluid revealed no indication of lymphoma, so the most likely diagnosis became exocrine pancreatic adenocarcinoma.

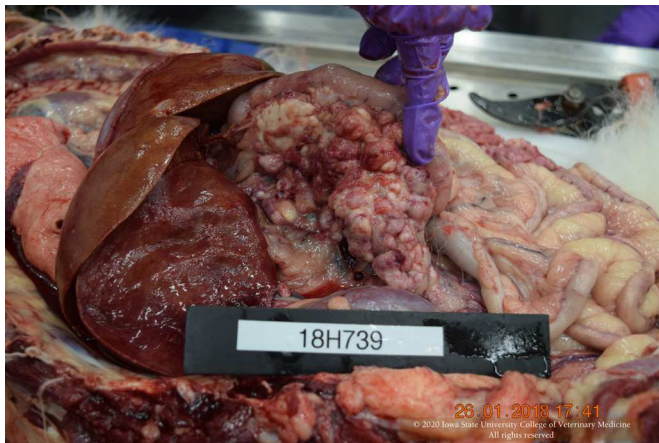## TREATMENT

Intravenous fluid diuresis with 0.9 per cent sodium chloride was initiated at 100 mL/kg/day. Fentanyl was administered intravenously at 3 to 5  $\mu\text{g/kg/h}$  as indicated for abdominal pain relief (response monitored via Colorado State University Canine Acute Pain Scale).<sup>8</sup> Supportive medical therapy included pantoprazole 1 mg/kg intravenously every 24 hours; maropitant 1 mg/kg intravenously every 24 hours; ondansetron 0.25 mg/kg intravenously every 8 hours; capromorelin 3 mg/kg orally every 24 hours. After 24 hours of hospitalisation when control of emesis was accomplished with antiemetic therapy, a nasogastric tube was placed for enteral nutritional support with 50 mL Clinicare Canine administered every 6 hours. An indwelling urinary catheter was placed to monitor and quantify urine production. Prednisone therapy was not instituted due to lack of definitive diagnosis, as lymphoma remained on the differential diagnosis list and prednisone treatment would make diagnosis challenging. Furosemide therapy was not instituted due to the dog's clinical hydration status in spite of intravenous fluid therapy. Bisphosphonate therapy was considered and discussed but not elected by the client.

## OUTCOME AND FOLLOW-UP

Despite aggressive supportive therapy for 48 hours, the dog's clinical status continued to decline. A subsequent CBC revealed more profound leucocytosis (44.67/ $\mu\text{L}$ , RI 6.0–17.0) composed of a neutrophilia (39.31/ $\mu\text{L}$ , RI 3.0–11.4) and mild left shift (893 band neutrophils/ $\mu\text{L}$ , RI 0–300) with slight toxic granulation and basophilia; and moderate normocytic, hypochromic, non-regenerative anaemia (haematocrit 24.4 per cent, RI 37–55; mean corpuscular haemoglobin concentration 30.7 g/dL, RI 32–36; absolute reticulocyte count 73 500/ $\mu\text{L}$ ). The repeated serum biochemistry profile showed persistent hypercalcemia (13.2 mg/dL, RI 9.7–11.3), elevated liver enzyme activities (alanine aminotransferase, ALT, 102 IU/L, RI 24–90; alkaline phosphatase, ALP, 709 IU/L, RI 20–150) and hyperbilirubinemia (total bilirubin 1.75 mg/dL, RI <0.1–0.6), marked azotemia (creatinine 5.3 mg/dL, RI 0.5–1.5; blood urea nitrogen 76 mg/dL, RI 10–30) and hyperphosphatemia (6.3 mg/dL, RI 3.2–6.0). Ionised calcium had improved slightly but remained elevated (1.61 mmol/L, RI 1.25–1.45).

Exploratory coeliotomy for pancreatic biopsy was discussed but not pursued by the client. Due to declining clinical status and quality of life, the development of acute kidney injury (AKI) and the clinical concern for a diagnosis of neoplasia with a grave prognosis, humane euthanasia was elected. Postmortem examination confirmed the diagnosis of exocrine pancreatic acinar adenocarcinoma with local extension to the mesentery, tunica muscularis of the adjacent duodenum and into the duodenal mucosa (figure 2). Multiple foci of necrosis and haemorrhage were noted within the pancreatic adenocarcinoma; no squamous differentiation was observed (figure 3). The clinical diagnosis of pancreatitis was supported and likely occurred via leakage



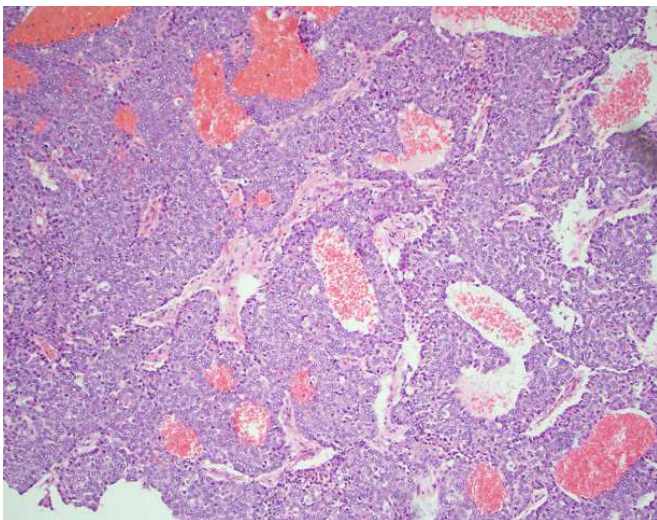
**Figure 2** Pancreatic tumour identified at postmortem examination.

of digestive enzymes from the neoplastic pancreatic epithelium. Regional metastasis of the pancreatic adenocarcinoma was observed to the liver, mesenteric lymph nodes and diffusely to the omentum, mesentery, gastrointestinal serosa and surface of the urinary bladder. Mild to moderate, multifocal, chronic glomerulosclerosis was noted within the kidneys.

Hypercalcemia panel results returned following euthanasia and indicated hypercalcemia (ionised calcium 2.04 mmol/L, RI 1.24–1.45), PTH at the low end of reference interval (0.70 pmol/L, RI 0.50–5.80) and markedly elevated PTHrP (7.9 pmol/L, RI 0.0–1.0 pmol/L). These findings were consistent with HM.

## DISCUSSION

Exocrine pancreatic adenocarcinoma is an uncommonly reported cancer in dogs with an estimated incidence rate of 17.8 per 100 000 patient years at risk.<sup>9</sup> Fewer than 100 cases of clinically or pathologically described canine exocrine pancreatic adenocarcinoma have been published in the veterinary literature since 1963.<sup>5</sup> Clinical signs tend to be non-specific and are often consistent with those seen in pancreatitis, including lethargy, vomiting, diarrhoea, abdominal pain, inappetence and weight loss.<sup>5,6</sup> Clinicopathology changes also often parallel those seen with pancreatitis, including neutrophilia and increased amylase,



**Figure 3** Histopathology of exocrine pancreatic adenocarcinoma.

lipase, cPLI and/or cTLI.<sup>5,6</sup> If extrahepatic biliary obstruction results from the presence of the pancreatic mass, increased liver enzyme activities (ALT, ALP) and total bilirubin may be observed.<sup>5,6</sup> The clinical utility of advanced diagnostic imaging (CT, MRI) is not well established for exocrine pancreatic adenocarcinoma, as much overlap occurs with pancreatitis.<sup>10</sup> While ultrasound-guided fine-needle aspirate cytology or biopsy has been shown to be helpful in obtaining a diagnosis,<sup>6</sup> coeliotomy for histopathology is often necessary for definitive diagnosis.<sup>5,10</sup> The case described here had many similar characteristics as those previously reported. History, clinical signs, physical examination findings and clinicopathology results, and diagnostic imaging findings were most consistent with pancreatitis. In this dog, however, marked hypercalcemia (with renal values within reference interval) was noted to have developed within a short period of time (total calcium was within reference interval at primary care veterinarian 3 days earlier). Marked elevation of PTHrP with low PTH confirmed HM.

Hypercalcemia of malignancy associated with exocrine pancreatic adenocarcinoma in dogs has not been previously reported in the veterinary literature. Lymphoma and AGASAC are the neoplasms most commonly associated with HM in dogs.<sup>1,3</sup> A number of other carcinomas are less frequently reported as causes of HM in dogs and have been previously summarised, including adrenal, hepatocellular, mammary, pulmonary, squamous cell, transitional cell and so on.<sup>2,3</sup> Hypercalcemia of malignancy associated with exocrine pancreatic adenocarcinoma is rarely reported in human oncology. When observed, HM is typically seen with adenosquamous carcinoma (ASC) of the pancreas and is accompanied by elevated levels of PTHrP.<sup>4</sup> ASC accounts for only 0.38 per cent to 10 per cent of all human exocrine pancreatic neoplasms. Diagnostic guidelines require the squamous component to comprise at least 30 per cent of the pancreatic neoplastic tissue in order to be classified as ASC.<sup>4</sup> It is believed to be the squamous component of the neoplasm that accounts for the PTHrP production.<sup>11</sup> In the case reported here, no squamous differentiation or component was observed on histopathology. While mammary,<sup>12</sup> pulmonary<sup>13–15</sup> and oesophageal<sup>16</sup> ASC have been reported in dogs, pancreatic origin has not. One case of pancreatic ASC in a cat has been published.<sup>17</sup>

As in this case, canine exocrine pancreatic adenocarcinomas are most commonly diagnosed at exploratory coeliotomy or postmortem examination.<sup>5,10</sup> The clinical prognosis is grave with reported survival times ranging from 1 day to several weeks; a few cases of hyalinising tubular pancreatic carcinoma have been reported with survival over a year.<sup>5,18</sup> Diffuse metastasis is common in pancreatic exocrine adenocarcinomas at the time of diagnosis or postmortem examination.<sup>5,6,19,20</sup> Hepatic metastasis is most common, but also seen in regional lymph nodes and infiltration on adjacent tissues, as seen in this case. Clinical benefit of adjunctive therapies such as chemotherapy or radiation therapy for canine exocrine pancreatic adenocarcinoma has not been documented.

The AKI experienced by this dog at the latter stage of the disease process likely resulted from the acute pancreatic inflammation associated with the underlying neoplasm and/or from the hypercalcemia itself. In this case, histopathology of the pancreas included marked inflammation that supported the clinical diagnosis of pancreatitis via leakage of digestive enzymes from the neoplastic pancreatic epithelium. A recent report identified AKI in 17/65 (26 per cent) of dogs with acute pancreatitis and this was associated with a poor clinical outcome.<sup>21</sup> The pathophysiology of renal injury associated with hypercalcemia has been previously summarised.<sup>2</sup>

Learning points

- ▶ Exocrine pancreatic adenocarcinoma in dogs can cause hypercalcemia of malignancy via production of parathyroid hormone-related protein. This is the first reported case in the veterinary literature. This should be a consideration in cases of hypercalcemia with pertinent pancreatic clinical signs and/or changes on diagnostic imaging.
- ▶ Clinical signs, clinicopathology findings and diagnostic imaging show significant overlap between pancreatitis and exocrine pancreatic adenocarcinoma (due to marked pancreatic inflammation associated with the neoplasm).
- ▶ Fine-needle aspirate cytology of exocrine pancreatic adenocarcinoma and/or associated free abdominal fluid may only yield inflammatory changes; histopathology is often necessary for definitive diagnosis of pancreatic neoplasia.
- ▶ Exocrine pancreatic adenocarcinoma in dogs is typically highly aggressive locally with distant metastasis often present at diagnosis. Treatment options are limited and rarely reported in the veterinary literature.
- ▶ Acute pancreatic inflammation and severe hypercalcemia can both be associated with acute kidney injury in dogs.

**Acknowledgements** The authors thank Jesse Hostetter, DVM, DACVP, University of Georgia, for his contribution in postmortem examination and anatomical pathology descriptions.

**Contributors** CMJ contributed to data collection, analysis of data and writing of the manuscript. EREH contributed to the management of the case, data collection and writing of the manuscript. MLM contributed to analysis of the data and preparation of the manuscript. CBA evaluated the pathology data and contributed to the writing of the manuscript.

**Funding** The authors have not declared a specific grant for this research from any funding agency in the public, commercial or not-for-profit sectors.

**Competing interests** None declared.

**Patient consent for publication** Not required.

**Provenance and peer review** Not commissioned; externally peer reviewed.

**Data availability statement** All data relevant to the study are included in the article.

**Open access** This is an open access article distributed in accordance with the Creative Commons Attribution Non Commercial (CC BY-NC 4.0) license, which permits others to distribute, remix, adapt, build upon this work non-commercially, and license their derivative works on different terms, provided the original work is properly cited, an indication of whether changes were made, and the use is non-commercial. See: <http://creativecommons.org/licenses/by-nc/4.0/>.

ORCID iD

Chad M Johannes <http://orcid.org/0000-0003-1855-6966>

REFERENCES

- 1 Mellanby RJ, Craig R, Evans H, et al. Plasma concentrations of parathyroid hormone-related protein in dogs with potential disorders of calcium metabolism. *Vet Rec* 2006;159:833–8.
- 2 Bergman PJ. Paraneoplastic hypercalcemia. *Top Companion Anim Med* 2012;27:156–8.
- 3 Messinger JS, Windham WR, Ward CR. Ionized hypercalcemia in dogs: a retrospective study of 109 cases (1998–2003). *J Vet Intern Med* 2009;23:514–9.
- 4 Borazanci E, Millis SZ, Korn R, et al. Adenosquamous carcinoma of the pancreas: molecular characterization of 23 patients along with a literature review. *World J Gastrointest Oncol* 2015;7:132–40.
- 5 Aupperle-Lellbach H, Törner K, Staudacher M, et al. Characterization of 22 canine pancreatic carcinomas and review of literature. *J Comp Pathol* 2019;173:71–82.
- 6 Bennett PF, Hahn KA, Toal RL, et al. Ultrasonographic and cytopathological diagnosis of exocrine pancreatic carcinoma in the dog and cat. *J Am Anim Hosp Assoc* 2001;37:466–73.
- 7 Holowaychuk MK. Hypocalcemia of critical illness in dogs and cats. *Vet Clin North Am Small Anim Pract* 2013;43:1299–317.
- 8 Hellyer PW, Uhrig SR, Robinson NG. Colorado State University Veterinary Medical Center canine acute pain scale. Available: [http://www.vasg.org/pdfs/CSU\\_Acute\\_Pain\\_Scale\\_Canine.pdf](http://www.vasg.org/pdfs/CSU_Acute_Pain_Scale_Canine.pdf) [Accessed 23 Apr 2020].
- 9 Priester WA. Data from eleven United States and Canadian colleges of veterinary medicine on pancreatic carcinoma in domestic animals. *Cancer Res* 1974;34:1372–5.
- 10 Selmic LE. Exocrine pancreatic cancer. In: Vail DM, Thamm DH, Liptak JM, eds. *Withrow & MacEwen's small animal clinical oncology*. 6th edn. St Louis: Elsevier, c2020: 451.
- 11 Trikudanathan G, Dasanu CA. Adenosquamous carcinoma of the pancreas: a distinct clinicopathologic entity. *South Med J* 2010;103:903–10.
- 12 Rasotto R, Berlato D, Goldschmidt MH, et al. Prognostic significance of canine mammary tumor histologic subtypes: an observational cohort study of 229 cases. *Vet Pathol* 2017;54:571–8.
- 13 Lee J-H, Lee J-H, Yoon H-Y, et al. Hypertrophic osteopathy associated with pulmonary adenosquamous carcinoma in a dog. *J Vet Med Sci* 2012;74:667–72.
- 14 Stewart J, Holloway A, Rasotto R, et al. Characterization of primary pulmonary adenosquamous carcinoma-associated pleural effusion. *Vet Clin Pathol* 2016;45:179–83.
- 15 Sato T, Ito J, Shibuya H, et al. Pulmonary adenosquamous carcinoma in a dog. *J Vet Med A Physiol Pathol Clin Med* 2005;52:510–3.
- 16 Okanishi H, Shibuya H, Miyasaka T, et al. Adenosquamous carcinoma of the oesophagus in a dog. *J Small Anim Pract* 2015;56:521–3.
- 17 Ogihara K, Madarame H. Pancreatic adenosquamous carcinoma with invasion to the spleen in a cat. *J Vet Med Sci* 2020. doi:10.1292/jvms.20-0244. [Epub ahead of print: 13 Jul 2020].
- 18 Dennis MM, O'Brien TD, Wayne T, et al. Hyalinizing pancreatic adenocarcinoma in six dogs. *Vet Pathol* 2008;45:475–83.
- 19 Chang S-C, Liao J-W, Lin Y-C, et al. Pancreatic acinar cell carcinoma with intracranial metastasis in a dog. *J Vet Med Sci* 2007;69:91–3.
- 20 Gutierrez-Quintana R, Carrera I, Dobromylyskiy M, et al. Pituitary metastasis of pancreatic origin in a dog presenting with acute-onset blindness. *J Am Anim Hosp Assoc* 2013;49:403–6.
- 21 Gori E, Lippi I, Guidi G, et al. Acute pancreatitis and acute kidney injury in dogs. *Vet J* 2019;245:77–81.

Copyright 2020 British Veterinary Association. All rights reserved. For permission to reuse any of this content visit <http://www.bmj.com/company/products-services/rights-and-licensing/permissions/>  
 Veterinary Record Case Reports subscribers may re-use this article for personal use and teaching without any further permission.

Subscribe to Vet Record Case Reports and you can:

- ▶ Submit as many cases as you like
- ▶ Enjoy fast sympathetic peer review and rapid publication of accepted articles
- ▶ Access all the published articles
- ▶ Re-use any of the published material for personal use and teaching without further permission

For information on Institutional Fellowships contact [consortiasales@bmjgroup.com](mailto:consortiasales@bmjgroup.com)

Visit [vetrecordcasereports.bvpublications.com](http://vetrecordcasereports.bvpublications.com) for more articles like this and to become a subscriber