

1944

Pseudopregnancy In Dogs

A. F. Weber

Iowa State College

Follow this and additional works at: http://lib.dr.iastate.edu/iowastate_veterinarian



Part of the [Small or Companion Animal Medicine Commons](#), and the [Veterinary Physiology Commons](#)

Recommended Citation

Weber, A. F. (1944) "Pseudopregnancy In Dogs," *Iowa State University Veterinarian*: Vol. 7 : Iss. 1 , Article 6.

Available at: http://lib.dr.iastate.edu/iowastate_veterinarian/vol7/iss1/6

This Article is brought to you for free and open access by the Student Publications at Iowa State University Digital Repository. It has been accepted for inclusion in Iowa State University Veterinarian by an authorized editor of Iowa State University Digital Repository. For more information, please contact digirep@iastate.edu.

Pseudopregnancy In Dogs

Relation to mammary neoplasms also discussed

A. F. Weber, '44

THE term pseudopregnancy was first used by Ancel and Bouin (1911) to describe an abnormally long luteal phase of the estrual cycle observed in the rabbit. Originally the term applied to the condition whereby, following copulation, no conception would take place, but that uterine and ovarian changes similar to those seen in pregnancy would ensue. It is now known that pseudopregnancy can occur in the virgin bitch following estrum when no copulation has taken place. It should be remembered that unlike the rabbit, ferret and other animals, the dog ovulates spontaneously, i.e., without the need of the copulation stimulus to cause the rupture of the follicle and consequent liberation of the ovum.

Index for Classification

To classify the various types of pseudopregnancy, it is suggested that the duration of the condition and the changes in the mammary gland be used as an index. In the case of the rabbit, rat and mouse, pseudopregnancy normally extends for about one-half the normal period of pregnancy. In these animals the complete growth of the mammary gland occurs, but the gradual initiation of lactation which normally develops during the second half of pregnancy does not appear. This condition has been called "incomplete pseudopregnancy." In the marsupial (*Dasyurus viverrinus*), the ferret and the dog, pseudopregnancy extends for a period comparable to the normal pregnancy and the development of the mammary gland includes the growth phase during the first half and the gradual initiation of lactation during the second half of the period. This condition is called "complete pseudopreg-

nancy."¹ In most cases the secretion of milk is not marked and its excretion into the lactiferous sinuses is even more rare.

In an article written on the post-estrual changes occurring in the generative organs and mammary glands of the non-pregnant dog, Marshall and Halman² conclude that pseudopregnancy is definitely a normal phenomenon in the bitch.

Since the pseudopregnant bitch acts normally and since the interval between two heat periods is long enough that the succeeding heat period is not interfered with, this condition in most instances escapes the attention of the owner. However, the accompanying mammary growth and development is evident. The amount of lactation present varies, but in some cases is so marked that the owner consults a veterinarian. Frequently there may develop an inflammatory swelling. A recent case presented at the small animal clinic at Iowa State College, to which the author will frequently refer, showed a marked mammary development and had been lactating for a period of 3 or 4 weeks before being presented for treatment.

Generally speaking, the dog has 2 breeding seasons per year. Some of the smaller breeds may have 3³. The majority of females come into heat during March or April, and again during September or October. Females first experience estrum at the age of 5 or 6 months. The history of the Springer Spaniel discussed in this article indicates that it either had a very incomplete, transient first heat period that went unnoticed, or that it did not come into heat until the eleventh month.

The normal heat period begins with the onset of proestrus, which lasts for 7 to 9 days. The cycle continues insensibly into

the period of the estrum which also lasts 7 to 9 days. Following this, there ensues the period of metestrum. During this interval the corpus luteum is at maximum size and activity. By the thirtieth day after the onset of metestrum, the corpus luteum has begun to involute and at the ninetieth day is completely involuted, at which time anestrus sets in. The anestrus period lasts about 2 months.

Proestrus

At the beginning of the proestrus period, the vulva shows an increasing amount of swelling and a clear sanguinary discharge is seen at the ventral commissure of the labiae vulvae. Throughout anestrus the endometrium is shallow, the epithelium low cuboidal with centrally located nuclei and the glands and crypts poorly developed. During proestrus and extending on into the first part of estrus, there is not much change in the parenchyma, but in the interstitial tissue of the endometrium there is a marked congestion and edema. The occurrence of some capillary hemorrhage accounts for the presence of a sanguinous discharge at the lips of the vulva.

At the end of the proestrus or beginning estrus, the ovarian follicle ruptures and the ovum is extruded. The ovum of the bitch is unique in that the first polar body has not been extruded at the time of ovulation. Consequently the egg is not mature and cannot be fertilized for a few days.

Estrus

By the sixth day of estrus the uterine glands have begun to show a marked activity. The epithelium is columnar, the crypts of the glands are well developed, more coiled and extend deeper into the endometrium. The epithelial cells show a marked granulation at this stage. The endometrium is becoming much deeper. This activity seems to have been initiated by the appearance of progesterone in the blood circulation. Progesterone is secreted by the cells of the stratum granulosum and theca interna of the corpus luteum, which begin their activity at the time of ovulation.

After ovulation the corpus luteum develops, becomes solid at the end of estrus or beginning metestrus and, as previously mentioned, remains fully developed for about 30 days when cellular degeneration begins.

The uterine complexity continues to develop and remains so until about the twentieth day of metestrus when involuntary changes set in. These continue until about the nineteenth day when the uterus passes into the anestrus or quiescent stage. During the zenith of their activity, the epithelial cells of the uterine mucosa are columnar, very much distended, have flat basally located nuclei and show a very granular cytoplasm. The granules are located principally in the portion of the cell facing the lumen. The gland lumina are small and contain a colloidal substance which stains pink to red with eosin.

Metestrus

Towards the end of the metestrus period the cells become less tall, contain a more spherical nucleus and are less granular. The lumina of the glands are larger and contain a considerable amount of colloid which stains as intensely as that seen during the middle of metestrus. Desquamated epithelial cells may be found in the lumina of the glands at this time. In accordance with reports in the literature⁴, the author has noted that around the forty-fifth day after the onset of metestrus, there is along with other retrogressive changes, a breakdown of capillaries in the endometrium and a subsequent extravasation of blood into the interstitial tissue. No sanguinous discharge is usually seen at this time because the epithelium of the uterine mucosa remains quite intact.

Before discussing the histological and physiological changes occurring in the uterus and ovaries during pseudopregnancy, it would be well to review the histology of the corpus luteum. After the rupture of the follicle and the discharge of the liquor folliculi and the ovum with its corona radiata, the wall of the follicle collapses. The epithelial membrana granulosa is thrown into folds and appears considerably thickened. The theca externa keeps its regular circular outlines while

the theca interna, on the contrary, loses them. At the base of the folds of the membrana granulosa the cells of the theca interna accumulate in triangular masses, while between the folds they are very scarce or absent⁵.

Formation of the Corpus Luteum

The principal role in the formation of the corpus luteum is played by the epithelial follicular cells. They begin at once to hypertrophy and in a few days attain a considerable size. Just when the formation of progesterone begins is a matter of speculation. Research workers report the rise of the progesterone level in the blood stream previous to the time of ovulation.

The lutein cell becomes polyhedral. The nucleus also swells and assumes a spherical form with a coarse chromatin network and one or two nucleoli. Mitoses are rarely found, leading to the presumption that the increase in size of the corpus luteum is due to cellular hypertrophy only. Such hypertrophied granulosa cells are called lutein cells although the lipid pigment "lutein" is at first found only in traces. The large lipid containing epithelioid cells of the theca interna remain scattered at the periphery of the folded layer of lutein cells and accumulate in the folds. Their inner structure is very similar to that of the lutein cells. They therefore have been given the name of "theca lutein cells" or "paralutein cells" while the true lutein cells of epithelial origin are designated as "follicular lutein cells."

The true lutein cells have a clear, slightly vacuolated cytoplasm which, though at first finely granular, shows a progressively greater accumulation of yellowish lipid material. The theca-lutein cells have the same structure but are smaller. Microchemical examination reveals in the true lutein cells in this stage the presence of lipoids, chemically close to carotin, of the phosphatid and cerebroside types. In the peripheral layers, especially in the theca-lutein cells, doubly refracting lipoids and cholesterol esters occur.

The polyhedral lutein cells are surrounded by a network of large, sinusoidal blood capillaries, the latter having a thin

endothelium. These lutein cells seem to be arranged in radial cords or strands. Between them networks of reticular fibers can be demonstrated by the silver impregnation method.

Before going directly into a discussion of the anatomical, histological and physiological aspects of the typical pseudopregnant animal, it would be well to conclude this discussion of the normal estral cycle in the dog by saying something about the hormones involved and their functions.

When the female approaches the age of puberty, the anterior lobe of the pituitary gland begins the production of significant amounts of follicular hormone (FSH). This causes the formation and development of ovarian follicles. Estrogens produced by the granulosa cells of a developing follicle stimulate the development of the accessory sex organs. As a result the uterine endometrium and myometrium show a marked increase in size and activity. In addition, these estrogens sensitize the tubular genital organs, making the action of the other hormones (progesterone, oxytocin) possible. Another function of the follicular hormone is to initiate duct growth in the mammary gland. It does this by initiating the secretion of mammogen I in the anterior lobe of the pituitary gland.

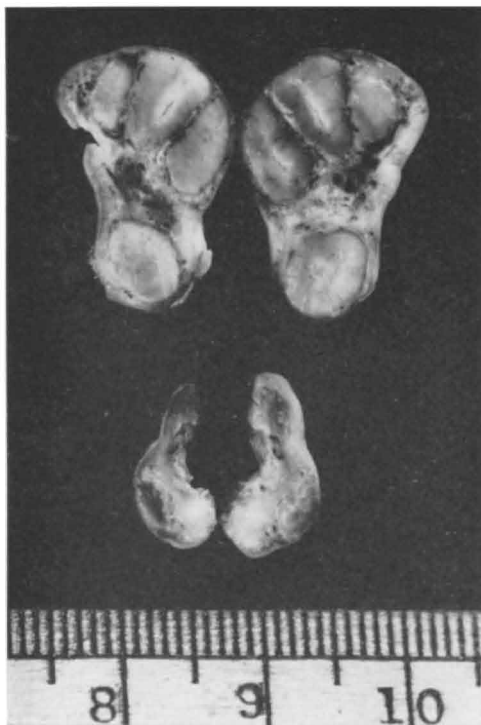Luteinizing Hormone

The increase of estrogen secretion causes the luteinizing hormone (LH) to be produced in the anterior lobe of the pituitary gland. This hormone is responsible for ovulation, preparing the uterus for the implantation of the fertilized ovum and the maintenance of pregnancy for at least part of its duration. A placental hormone similar to progesterone assumes this function during the remainder of the pregnancy period. In addition, progesterone initiates the secretion of mammogen II from the anterior lobe of the pituitary gland. The latter hormone, called the lobulo-alveolar factor, is responsible for the formation and development of the terminal acini in the mammary gland.

The progesterone level remains quite high until just after parturition. Toward the end of pregnancy the estrogen level in-

creases in magnitude until it overrides the action of progesterone. Estrogen sensitizes the uterus so that oxytocin, a hormone produced in the posterior lobe of the pituitary, can initiate uterine muscular activity and thereby bring about the expulsion of the fetus.

Prolactin, secreted by the cells of the anterior lobe of the pituitary gland, then initiates secretory activity in the mammary gland. Whether or not the increased estrogen production is responsible for the production of prolactin is a matter of speculation.



Top. Ovary from dog in metestrus. Increase in size due to cellular hypertrophy of luteal cells. **Bottom.** Ovary from pseudopregnant bitch in which corpora lutea are much reduced in size.

Since the female Springer Spaniel spoken of previously in this discussion presented such an exact duplication of a typical case of pseudopregnancy, a detailed histological study was made of her uterus and ovaries. During the latter part of February, 1944, the owner first noticed the dog in estrus. At that time she was 11 months old. The bitch was kept indoors so no copulation took place

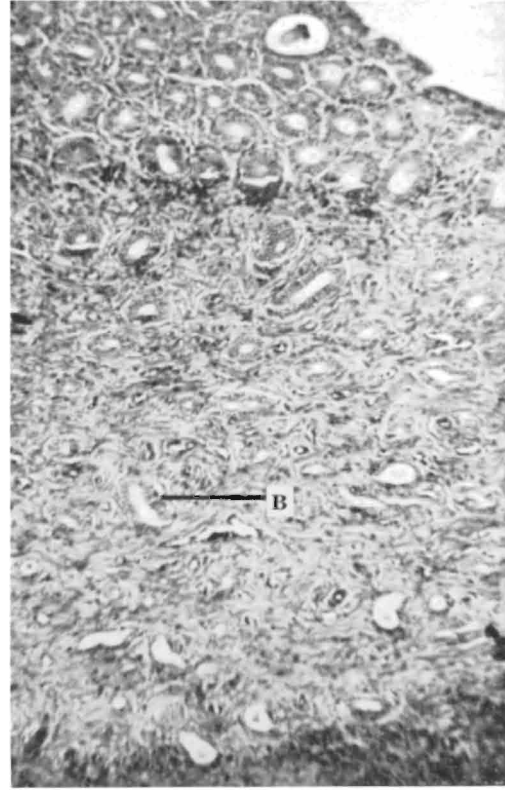
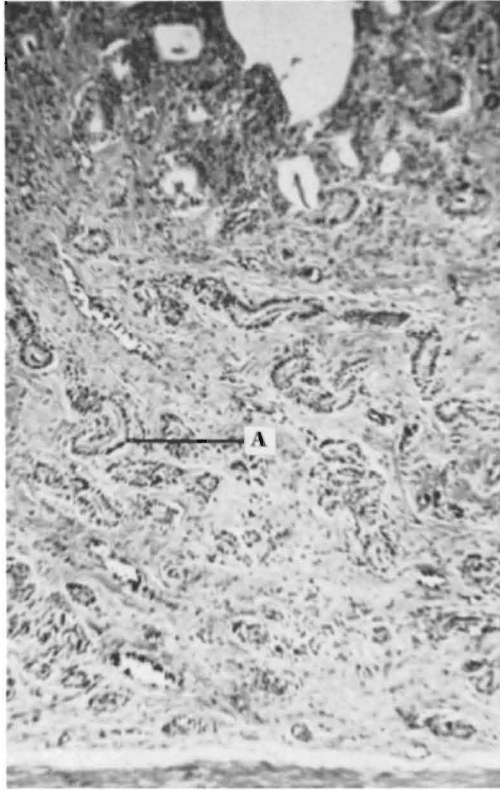
during the heat period. About May 1, or approximately 60 days after ovulation and conception would have taken place under ordinary circumstances, the animal began to lactate. The enlargement of the mammae took place slowly. When the case was presented at the clinic it had been lactating for a period of 3 or 4 weeks. No other pertinent external manifestations were noticed and the disposition of the animal was the same as it had been previously. At the request of the owner an oophorohysterectomy was performed.

The ovaries and uterus were placed in 10 percent formalin fixing fluid for 24 hours and then stored for several days in 70 percent ethyl alcohol. The routine dioxane-paraffin method was used to dehydrate, clear, infiltrate and imbed the tissues. A Weigert's-Heidenhain's-Van Gieson's picrofuchsin staining routine was followed in preparing the sections for study. All sections were cut 6 microns thick.

Histology

From the histological studies made, it was determined that the stage of pseudopregnancy had reached its zenith and that signs of beginning retrogression were evident. The endometrium of the uterus was beginning to show some signs of involution and a number of young ovarian follicles contained well developed follicular cavities filled with liquor folliculi. The uterine endometrium was as deep as that seen during metestrus and the coiled uterine glands extended to the myometrium. The epithelial cells of the glands were columnar in the neck and body portions, but cuboidal at the bases of most glands. It was here that involution was most noticeable. The cuboidal cells and the columnar cells in most instances contained a central nucleus. Very little granular material could be seen in the cytoplasm. The lumina of the glands were much larger and contained a limited amount of colloidal material and epithelial cell debris. This material stained rather lightly.

There was some hemorrhage seen in the superficial portions of the endometrium. It was very similar to that seen accompanying the involutionary changes occurring at the termination of the metestrus



Left. Endometrium of metestrum uterus. **A.** Portion of gland showing basally located nuclei and small acinus filled with secretory products.
Right. Endometrium of pseudopregnant uterus. **B.** Portion of gland showing centrally located nuclei and a large lumen. $\times 100$.

in the normal cycle. The musculature of the myometrium was extremely well developed. The nuclei and cytoplasm of the outer longitudinal smooth muscle layer stained much more intensely than those of the inner circular layer.

The ovaries were markedly smaller than those taken from bitches in the metestral stage of the sexual cycle. As previously mentioned, there were numerous small follicles present, some of which had follicular cavities.

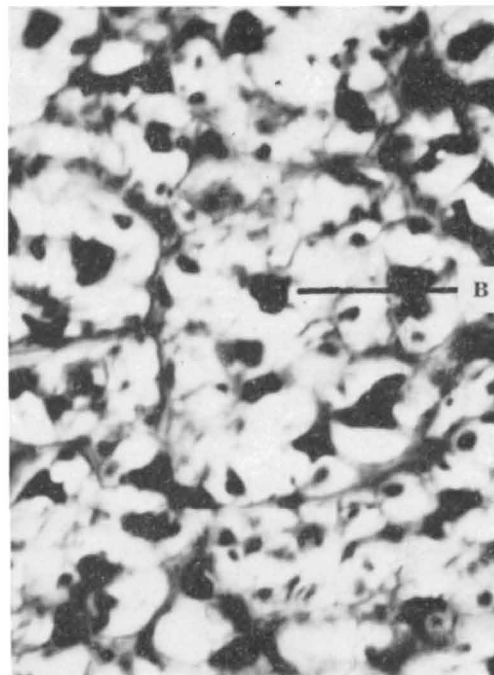
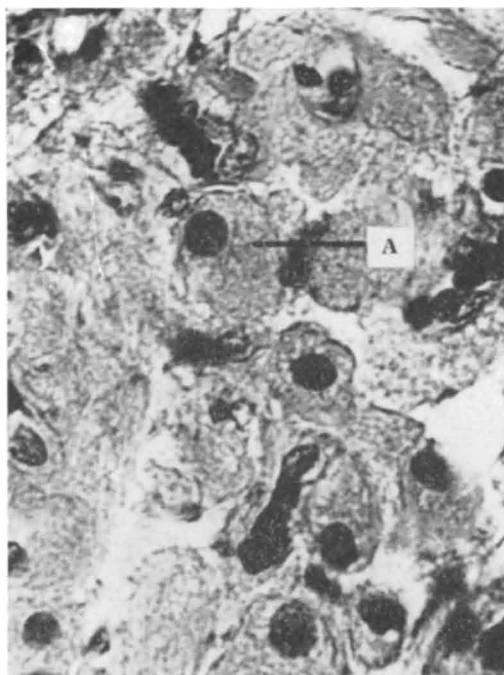
Hormonal Relationship

One of the most controversial subjects in the discussion of pseudopregnancy is the hormonal relationships. Several theories have been propounded concerning the antagonistic and synergistic action of the follicle stimulating hormone (FSH), the luteinizing hormone (LH), estrone and progesterone in the normal cycle. A com-

monly accepted theory is that the follicle stimulating hormone causes the growth and development of the young follicle. In turn the estrogens secreted by it stimulate the production of luteinizing hormone. This luteinizing hormone causes the granulosa cells of the ovary to secrete progesterone, which in turn inhibits the formation of follicular stimulating hormone. Thus the estrogen level is reduced. Since estrogen stimulated the production of luteinizing hormone, the latter is produced in less amounts and the progesterone level must necessarily fall. If pregnancy has ensued in the meantime, the progesterone-like hormone secreted by the placenta is sufficient to carry the fetus until parturition. The placental hormone does not inhibit the formation of follicle stimulating hormone (FSH) and consequently the estrogen level is seen to rise towards the end of pregnancy.

In pseudopregnancy as seen in the bitch, there is a disturbance in this hormonal relationship. From histological studies made of the ovaries of the pseudopregnant Springer Spaniel bitch, the progesterone level was estimated as not being very high. Large vacuoles, presumably containing neutral fat, were found in practically all of the lutein cells. As contrasted to this, luteal cells examined in the corpora lutea of bitches in the metestrus period

through the anterior pituitary to produce ovarian development and the formation of corpora lutea. Since the virgin bitch may become pseudopregnant, it is evident that the copulation stimulus is not needed to initiate pseudopregnancy. It is not unreasonable to believe that the lack of a nervous stimulation to the cells of the anterior pituitary producing follicular stimulating hormones is responsible for the failure of estrogen to override the



Left. Corpus luteum cells of metestrus ovary. A. Cell shows a few small vacuoles. Right. Corpus luteum cells of pseudopregnant ovary. B. Cells much vacuolated due to dissolving of neutral fat from cytoplasm by fat soluble fixatives. $\times 960$.

revealed the presence of small numbers of rather small vacuoles. At this time the amount of progesterone secreted is very large. Nevertheless, without the presence of a considerable amount of progesterone to act as an inhibitor (on the cells secreting follicular stimulating hormone), the estrogen level was low. That it was low was concluded from the fact that the ovarian follicles were very immature.

Theory of Cause

Cameron⁶ states that pseudopregnancy in the rabbit is probably due to a nervous reflex set up through copulation acting

effect of progesterone and terminate the luteal phase of the cycle.

There are various methods of treating the pseudopregnant condition of the bitch. These will vary according to the age of the animal, the amount of mammary enlargement and the purpose for which the animal is kept.

In a few instances where there is mammary development to the point where the swelling becomes painful, symptomatic treatment is sufficient. If the owner desires to use the animal for breeding purposes, anterior pituitary hormone (FSH), one of the naturally occurring estrogens, or

one of the synthetic estrogens such as diethylstilbestrol can be used. There are no clinical reports in the literature concerning the therapeutic value of these products. Morphine has been used with some success. The nature of its action is uncertain. Where the owner keeps the animal as a pet or servant, an oophorohysterectomy can be performed.

Relation to Tumors

Although neoplastic enlargements in the mammae appear or increase in size during proestrus, estrus and early metestrus, many cases of this kind occur at a later stage in the cycle and often in connection with pseudopregnancy. Likewise, although mammary tumors are spoken of by many authors as being the result of an abnormally high estrin blood titre during the follicular phase of the sexual cycle, some have recognized neoplastic formations to be associated with an abnormally high progesterone blood level.

McClelland⁷ states that whereas the owner "thinks that the growth occurred after the pups were born," more often it is noted several years after the last breeding or in aging virgin bitches. Many times there is a history of an irregular estrual cycle and lactation without pregnancy (pseudopregnancy).

De Vitta⁸ states that non-pregnant lactation is frequently noted following estrus during one or more estrual cycles previous to the incidence in animals where neoplasms develop.

Most mammary tumors are of a benign nature, but many are malignant. In the literature many types of both, such as fibromas, fibrosarcomas, adenomas, adenofibromas, adenocarcinomas, mixed tumors chondromas and osteomas have been described. Adenofibromas, commonly referred to as chronic cystic mastitis, are frequently associated with a hyperplasia of the endometrium and cystic ovaries. All of the above mentioned types have been observed in connection with pseudopregnancy.

Animals presented for treatment range from 8 to 14 years of age. Boston Terriers, according to one report⁸ comprised 43

percent of the cases presented with mammary tumors. Of the cases presented, 27 percent were malignancies, 18 percent were mixed tumors, and 48 percent were adenofibromas (chronic cystic mastitis).

Often the mass lies within or near the nipples and nodules are seen flaring up coincident with the onset of estrus. Cyst-like formations begin to enlarge and appear as soft, blue areas beneath the skin. Many rupture and discharge a bloody fluid. Where the parenchyma is involved, a cystic dilatation of the ducts of the teat and occasionally of the lactiferous tubules is seen. A hyperplasia and papillomatosis of the duct epithelium commonly occurs. In many instances mammary tumors are sclerotic, resembling cartilage and bone.

Treatment

The best method of treatment, regardless of whether the condition is caused by an estrogen or progesterone blood level disturbances, is oophorohysterectomy. If the tumor is of a malignant nature, it should be removed immediately and the ovaries and uterus removed as soon as the animal is capable of undergoing another operation. De Vitta reports that an oophorectomy will prevent their occurrence as well as recurrence, and that following oophorohysterectomy benign tumors regress in many instances without removal, provided they are not sclerotic.

REFERENCES

1. Turner, C. W. and DeMoss, W. R. 1934. The normal and experimental development of the mammary gland. Res. Bul. 207. Agr. Exp. Sta., College of Agr., Univ. of Missouri.
2. Marshall, F. H. A. and Halman, E. T. 1916. On the post-oestrus changes occurring in the generative organs and mammary glands of the non-pregnant dog. Proc. Roy. Soc. of London. Series B. 89:546-558.
3. Dukes, H. H. The Physiology of the Domestic Animals. Comstock Pub. Co., Inc., Ithaca, N. Y. 1943.
4. Keller, Karl. 1909. Über den bau des endometriums beim hunde mit besonderer berücksichtigung der cyklischen veränderungen bei den uterindrüsen. Anatomische Hefte; Erste Abteilung; 39 Band; 117, 118, 119 Hefte.
5. Maximow, A. A. and Bloom, Wm. A Textbook of Histology. W. B. Saunders Co., Philadelphia. 1941.
6. Cameron, A. T. Recent Advances in Endocrinology. Blakiston Co., Philadelphia. 1940.
7. McClelland, Robert B. 1941. Tumors of the mammary gland in dogs. No. Am. Vet. 22(8):491-493.
8. DeVitta, Joseph. 1939. Mammary adenofibroma of the female dog. No. Am. Vet. 19(3):53-55.