

1959

Central Nervous System Symptoms and Brain Damage Associated with Common Ruminant Digestive Disturbances

B. W. Donelan
Iowa State College

C. W. Howe
Iowa State College

Follow this and additional works at: https://lib.dr.iastate.edu/iowastate_veterinarian

 Part of the [Large or Food Animal and Equine Medicine Commons](#), and the [Veterinary Pathology and Pathobiology Commons](#)

Recommended Citation

Donelan, B. W. and Howe, C. W. (1959) "Central Nervous System Symptoms and Brain Damage Associated with Common Ruminant Digestive Disturbances," *Iowa State University Veterinarian*: Vol. 21 : Iss. 2 , Article 11.
Available at: https://lib.dr.iastate.edu/iowastate_veterinarian/vol21/iss2/11

This Article is brought to you for free and open access by the Journals at Iowa State University Digital Repository. It has been accepted for inclusion in Iowa State University Veterinarian by an authorized editor of Iowa State University Digital Repository. For more information, please contact digirep@iastate.edu.

On the sixth day the temperature, heart rate and respiration were normal; the animal had a bright alert look, was ruminating, eating regularly and the feces were normal. The cow was ordered home.

Gordon R. Miller '60
Sterling L. Schelkopf '60

2 **Central Nervous System Symptoms and Brain Damage Associated with Common Ruminant Digestive Disturbances.** With the exception of the optic papilla, the nervous system is not subject to direct examination. Diagnosis of diseases of the nervous system must, therefore, be made by interpretation of symptoms. These symptoms are manifested as disturbances of consciousness, locomotion, senses, incoordination and motor irritation.

The following cases are cited to illustrate central nervous system symptoms and brain damage associated with two common field cases of ruminant digestive disturbances. Intoxications involving the digestive tract may be a cause of motor irritation and nervous excitement.

Rumen Indigestion

During the evening of Dec. 14, 1958, two 10-month old Hereford heifers were admitted to the I.S.C. Veterinary Clinic with a history of having been turned into the cornstalks several weeks previously. The animals were showing incoordination.

The following morning one animal was dead. The other was weak, incoordinated, trembling and at times was unable to rise. From time to time she would grit her teeth and periodically the large muscles showed "strychnine-like" contractions. She had a watery diarrhea and her temperature was 102.4. The heart beat was very rapid and the pulse weak.

Post mortem examination of the dead heifer revealed a sour smelling material throughout the entire digestive tract. The rumen was filled with material in an advanced state of decomposition.

A diagnosis of rumen intoxication was made.

The living heifer was treated with 350 cc. of 50 percent dextrose I.V. and considerable improvement was noted the following day. Although still unsteady, the animal could stand and eat some hay. The patient was retreated with dextrose. The following day the animal was unsteady on her feet, but could eat hay and grain. When released to go home, one could still detect some incoordination in the rear quarters with a slight bobbing of the head.

The continued consumption of cornstalks may have been the cause of a variable degree of indigestion due to the inability of the rumen microorganisms to adjust to this new type of feed. Over a period of many days ingesta accumulated in various stages of decomposition. The toxins absorbed from this decomposing mass of ingesta gradually depleted the detoxifying power of the body. The selective absorption of the rumen epithelium may be altered, resulting in passage of toxins from the mass of ingesta directly into the blood stream. The inability of the body to detoxify all the toxins may lead to hyperemia and finally demyelination necrosis of some of the brain tissue.

Coccidiosis

On Dec. 9, 1958, two 8-month-old Hereford heifers were admitted to the I.S.C. Veterinary Clinic with a history of having had a diarrhea.

Physical examination of one of the heifers revealed a temperature of 104.4. She was reported as being very excitable and going into tetanic convulsions when moved. Laboratory examination of the feces revealed numerous oocysts.

Post mortem examination of one of the animals revealed the following: hyperemia of the terminal portion of the small intestine, focal areas of hemorrhage and linear ulcers in the spiral colon, severe diffuse, epithelial erosions of the entire cecum, and hemorrhagic proctitis. Scrapings of the cecum contained large numbers of *Eimeria zurnii*. A diagnosis of coccidiosis was made.

During the subsequent recovery of

the remaining animal, the digestive processes and feces returned to normal. The appetite improved and the degree of hyperexcitability, trembling and incoordination was greatly reduced. There remained, however, evidence of brain damage.

In this case, an overwhelming number of coccidia in the intestinal epithelium, and the associated tissue destruction could possibly be the source of toxins. The toxins may also be of enteric origin causing damage to the intestinal epithelium and are absorbed because of altered permeability or selective absorption of the intestinal mucosa.

Some central nervous system symptoms may be caused by intoxications that are the result of gradual depletion of the detoxifying processes of the body. There may be some permanent brain damage from these intoxications, resulting in an incomplete recovery.

B. W. Donelan '59

C. W. Howe '59

3

Cervical Arthritis in the Dog.

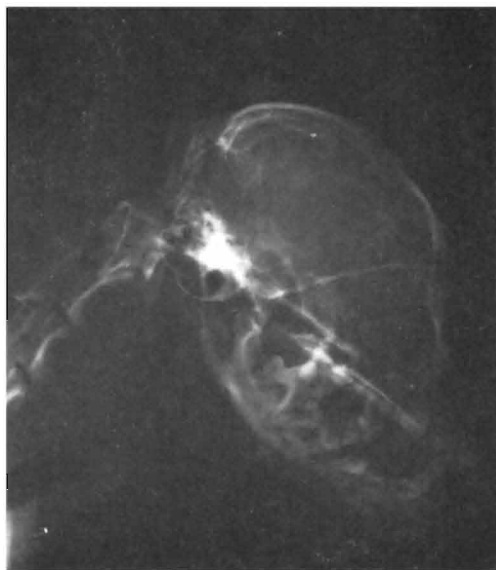
On Oct. 4, 1958, an 8-year-old spayed female dog of the Pomeranian type was presented to Stange Memorial Clinic. The dog had a very stiff, tense neck which could not be moved without the animal eliciting extreme pain. The condition had first appeared last April and became progressively worse.

On examination it was observed that the neck could not be moved from side to side or up and down without a great deal of discomfort to the dog. It was noted that the teeth needed cleaning. A total leucocyte count was made and found to be within the normal limits.

The dog was given 200 mg. of Butazolidin (Jensen. Salsbery's brand of phenylbutazone) daily for three days. No apparent relief was evident within that time, consequently, one tablet of V-Sinan (Mephenesin) was administered twice daily.

On October 10 an x-ray was taken of the head, cervical and anterior thoracic area. The radiograph revealed several interesting facts. There was a cervical

arthritis, evidenced by a "lipping" of several of the cervical vertebra. It was also evident that a number of teeth were involved with abscesses at their roots.



Radiograph of head and neck showing abscessed molars and "lipping" of first few cervical vertebra.

It was thought that the teeth were a definite etiological factor in the cervical arthritis. The dental involvement appeared to be one that had existed for a long period of time. It was thought that toxic substances from the abscesses were drained by the vertebral venous system and caused the arthritis to occur. It was theorized that a stagnation of the toxic substances occurred in the veins in the cervical region because the vertebral veins do not have valves and eventually produced an arthritis. Similar cases of arthritis of the vertebra of the lumbar area have been known to occur as the result of a chronic prostatic infection.

The dog was anesthetized with 3 cc. of 4 percent Surital (Parke-Davis & Co.) and all visually involved teeth were extracted. One cc. of Antibiotic Combination No. 1 (Corn States Lab. penicillin and streptomycin) was given twice daily until the day of the dog's release. By October 14 the dog showed a marked improvement and the animal was discharged the following day.

Robert L. Maahs '59