

1984

# Photoradiation Therapy

Sherri L. Ihle  
*Iowa State University*

Ronald L. Grier  
*Iowa State University*

Follow this and additional works at: [https://lib.dr.iastate.edu/iowastate\\_veterinarian](https://lib.dr.iastate.edu/iowastate_veterinarian)

 Part of the [Neoplasms Commons](#), [Oncology Commons](#), [Radiology Commons](#), [Therapeutics Commons](#), and the [Veterinary Medicine Commons](#)

---

## Recommended Citation

Ihle, Sherri L. and Grier, Ronald L. (1984) "Photoradiation Therapy," *Iowa State University Veterinarian*: Vol. 46 : Iss. 1 , Article 1.  
Available at: [https://lib.dr.iastate.edu/iowastate\\_veterinarian/vol46/iss1/1](https://lib.dr.iastate.edu/iowastate_veterinarian/vol46/iss1/1)

This Article is brought to you for free and open access by the Journals at Iowa State University Digital Repository. It has been accepted for inclusion in Iowa State University Veterinarian by an authorized editor of Iowa State University Digital Repository. For more information, please contact [digirep@iastate.edu](mailto:digirep@iastate.edu).

# Photoradiation Therapy

Sherri L. Ihle\*

Ronald L. Grier, DVM, PhD\*\*

**Editor's note:** Currently, photoradiation therapy is not performed in the Veterinary Teaching Hospital at Iowa State University.

## Introduction

One of the most difficult areas of both human and veterinary medicine today is the treatment of neoplastic disease. Numerous techniques and agents have been used in this field but none are totally effective. The variability of responses to treatment is as wide as the variety of cancerous conditions. For this reason, research continues to search for safer, more effective methods of cancer therapy. One development in this area is phototherapy, or more exactly, photoradiation therapy (PRT). This technique was expanded to include its use in pets.<sup>21</sup>

Photoradiation therapy involves use of a photoactive drug which localizes in neoplastic and dysplastic tissues while at the same time rapidly clearing from normal tissues. Illumination with red light electronically excites the compound in the malignant tissue; energy is released, cell components oxidize and cell death occurs. Normal tissue is thus spared while malignant tissue is destroyed.<sup>1</sup>

## History

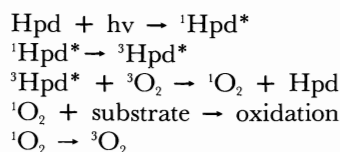
The theory that drugs cause a photosensitivity reaction in tissues is not new.<sup>2</sup> Thirty years ago it was noted that hematoporphyrins accumulated in embryonic, neoplastic, and regenerating tissues, and in lymph nodes. Tumors fluoresced a red color when illuminated with ultraviolet light after injection of a crude hematoporphyrin compound. In 1960 a purified compound, hematoporphyrin derivative

(Hpd), was found to have a superior tumor-localizing ability.<sup>3</sup> In 1973 the Mayo Clinic reported the use of fluorescence bronchoscopy in early lung cancer. However, the fluorescence was faint and hard to document and so the project was discontinued.<sup>2</sup> The first reported case of complete tumor destruction of experimental tumors was in 1975 when Hpd was used with local application of red light the following day. In 1976 this treatment was used on a human bladder carcinoma with light application via a transurethral quartz rod.<sup>4</sup>

## Biochemistry

While Hpd is selectively retained by malignant tissue it is also retained by liver, kidney, spleen, and lymph.<sup>5</sup> Studies indicate that the relative hydrophobicity of a porphyrin is very important to both its localization and tissue toxicity. More hydrophilic agents do not accumulate well and therefore are very poor photosensitizers of intact cells. The porphyrin structure also affects the toxic products formed and the speed of their formation. Studies showed that hematoporphyrin has difficulty crossing cell membranes; localization in malignant tissues occurs as a result of intercellular conversion of a permeable derivative to hematoporphyrin or another poorly diffusible component.<sup>6</sup>

How are such toxic compounds formed and how do they destroy the tissues? The reaction is a photo-initiated oxidation in which energy is transferred from the Hpd to tissue oxygen, forming singlet oxygen:



\*Ms. Ihle is a fourth-year student in the College of Veterinary Medicine at Iowa State University.

\*\*Dr. Grier is a professor of Veterinary Clinical Sciences at Iowa State University.

In this reaction  $^1\text{Hpd}^*$  is the excited state of Hpd,  $^3\text{Hpd}^*$  is the excited triplet state of Hpd,  $^3\text{O}_2$  is ground state triplet oxygen and  $^1\text{O}_2$  is the excited triplet state of oxygen.<sup>7,8</sup>

The occurrence of such a reaction has been inferred from the protective effect provided by the presence of natural or added carotenoids which are well-established quenchers of singlet oxygen. Using 1,3-diphenylisobenzofuran as a quencher of photoactivation, studies have confirmed that singlet oxygen is the likely cytotoxic agent with this type of therapy.<sup>8</sup> Immediately after exposure to PRT, coagulation of erythrocytes occurs in tumor vessels where the porphyrin levels are highest. Death of nearby cells occurs and more distant cells become less tightly packed. Electron microscopy shows that cells nearest the vessels are actually emptied of cytoplasmic contents which have leaked into the interstitium. Within three hours gross necrosis and massive cell destruction are seen. This is a manifestation of inhibition of membrane transport, membrane damage due to photodynamic crosslinking of membrane proteins and lipids, and damage to DNA and lysosomes. Survival curves for cells containing Hpd are similar to those resulting from ionizing radiation.<sup>7</sup>

Having established that such a reaction occurs, it was desirable to find a light source producing wavelengths of 620–640 nanometers. This range was found to produce optimal results since visible wavelengths greater than 600 nm are least absorbed by skin and other tissues, and porphyrins show weak absorption in this part of the spectrum. Arc lamps, fluorescent lights and other strong light sources will deliver enough light to treat superficial tumors when fitted with appropriate filters.<sup>9</sup> Deeper tumors require a different method of light delivery. New developments in lasers and fiberoptics can be used to allow illumination of nearly any portion of the body without major surgery. In man, tumors up to 5cm × 5cm have been destroyed by use of multiple fiber techniques.<sup>10</sup>

### Human Medicine Applications

Many preclinical tests and trials of PRT have been done in man. In all cases the lesions treated have been inoperable and have failed to respond to conventional therapy. The amount of Hpd used, the wavelength and duration of light exposure and many other parameters have been studied. Favorable response oc-

curred with many types of neoplasia and in numerous anatomical locations. PRT has also been shown to be effective in localization of some malignancies.

PRT has been used to treat squamous cell carcinoma of the tracheobronchial tree in 10 patients.<sup>11</sup> Laser beams were used to deliver light through a bronchoscope. Complete response (no tumor demonstrable in a biopsy or brush preparation) was seen in four cases, and a partial response (greater than 50% decrease in tumor size) occurred in five patients. All masses had been small superficial tumors. The remaining patient died from hemorrhage and cardiac arrest secondary to the neoplasm eroding the wall of a major bronchus.<sup>11</sup>

In Australia, researchers used Hpd and a laser/fiberoptic system to treat 20 superficial and seven deeper tumors which included mammary carcinoma and other carcinomas, malignant melanoma, chondrosarcoma and glioma. The best clinical results were seen with superficial tumors, with a positive response in 17 of 20 cases. Complete tumor necrosis occurred in five. There was no response in two malignant melanomas and a metastatic chondrosarcoma. Of the seven tumors, only the glioma showed any response (See Table 1).

Two studies with PRT have been done at the University of California on dermal breast cancer recurrence, local recurrence of head and neck squamous cell carcinoma, and other carcinomas. One study reported a 67% favorable response involving treatment of 128 sites. The best response was against local recurrence of head and neck squamous cell carcinoma and recurrence of breast cancer with an 85% and 70% response rate respectively. A lesser response was seen with metastatic squamous cell carcinoma in which the tumors were usually larger, ulcerated and more severe at the time of treatment. Response was evaluated 30 days post-treatment; a positive response was defined as either complete or partial.<sup>12</sup> In another study from the University of California, PRT was used on 267 tumor sites which included dermal breast carcinoma recurrence, head and neck squamous cell carcinoma recurrence and cutaneous metastasis. An 81% positive response rate was seen (complete and partial response). Some patients with recurrent breast cancer experienced significant pain for up to three weeks following treatment. Interestingly, while 84 tumors responded favorably, only 25% of these had an effect on the course of the disease.

**TABLE 1 Current statistics for tumor responses to phototherapy (6/1/83)**

Tumor	No.	Response			No Follow-up
		Complete*	Partial	None	
Adenocarcinoma (Mammary—Cat)	5	5			
Adenocarcinoma (Undifferentiated)	3	1	2		
Adamantinoma	4	4 <sup>(3)*</sup>			
Eosinophilic Granuloma	1		1		
Fibromatous Epulis	2	1 <sup>(1)*</sup>			1
Acanthomatous Epulis	1	1			
Fibroma	1	1			
Fibrosarcoma	7	2 <sup>(2)*</sup>	4	1	
Hemangiopericytoma	1		1		
Hemangiosarcoma	1	1			
Leiomyosarcoma	1		1		
Liposarcoma	1	1			
Malignant Mast Cell	12	9 <sup>(2)*</sup>	2		1
Malignant Melanoma (Melanotic)	4	3 <sup>(2)*</sup>	1		
Malignant Melanoma (Amelanotic)	3	2 <sup>(1)*</sup>	1		
Mastocytoma	1	1			
Myxoma	2		1	1	
Osteosarcoma (Head)	6	3 <sup>(3)*</sup>	2	1	
Osteosarcoma (Limb)	3		1 <sup>?</sup>	2	
Perianal Gland Sarcoma	1	1			
Sarcoma (Undifferentiated)	2	2			
Sebaceous Gland Sarcoma	1	1 <sup>(1)*</sup>			
Sebaceous Gland Carcinoma	1	1			
Squamous Cell Carcinoma	8	3 <sup>(1)*</sup>	4		1
Synovial Cell Sarcoma	3	1	2		
Total types:25	75	44 or 59%	23 or 31%	5 or 7%	3 or 4%

90% Total positive response

(\*Number in parentheses are those in complete remission for more than one year.)

[Thoma, Stein, Weishaupt, and Dougherty: Phototherapy: a promising cancer therapy. *VM/SAC* 78:1965, 1983.]

Many patients developed new lesions in untreated areas. Patients with cutaneous metastatic head and neck tumors did not do well, but those with local recurrence benefitted considerably with a major change in disease progression.<sup>12,13</sup>

Several other anatomical locations and tumors have been treated with PRT. The Japanese have reported complete regression of early vaginal carcinomas with PRT treatment, with no recurrence at one-year follow-up.<sup>14</sup> Hpd and a laser light source have been used to treat retinoblastomas and intraocular malignant melanoma of the choroid. Treatment in this area is normally difficult, as adjacent normal tissue must be spared. Radiation therapy results in radiation burn of nearby tissue. This problem does not occur with PRT if the light intensity remains less than 200 milliwatts/cm<sup>2</sup>.<sup>15</sup> PRT is also being considered for malignant brain tumors. Some work has been done in this area, but conclusions cannot be drawn at this time.<sup>16</sup>

An interesting facet of current PRT research is the use of Hpd and fluorescence bronchoscopy for the detection and localization of bron-

chial and lung cancer. In the past when sputum cytology suggested neoplasia, a brush biopsy or tissue biopsy had to be prepared. These procedures were often difficult to perform if the lesion could not be visibly differentiated from the surrounding tissue. With PRT, Hpd was given intravenously and the areas were checked three hours later for fluorescence. The results were quite favorable with fluorescence seen in 32 of 34 malignancies. No false positives were seen in the eight benign lesions. A few false positives were seen in areas of lymphoid tissue, but this was not a problem since all true positives were later confirmed by biopsy. False negatives are more of a problem since the lesion could then be missed.<sup>17,18,19</sup> This same technique for localization of neoplasia has been used on bladder carcinoma. Biopsies of visually suspicious areas have previously been the primary method of confirming positive urine cytology. Subtle or diffuse disease was often missed by this method, however. Hpd given intravenously two hours pre-surgery will localize in dysplastic and neoplastic transitional cells and be detected by subsequent fluorescence.<sup>20</sup>

Side effects have been relatively mild. Slight pain has been experienced in a few cases and some discomfort has been associated with resultant tumor necrosis. The main complication is photosensitivity for 2–4 weeks post-treatment. This can be prevented however, if the patient avoids exposure to sun during this time. A few patients who have ignored this advice have incurred skin burns.

### Veterinary Medicine Applications

PRT has been used in pet dogs and cats in the past few years. The animals used in this ongoing study were chosen because of their failure to respond to conventional therapy or because they could not tolerate therapy. Some pets had surgical excision of tumor with PRT used as adjunct therapy. The pets were obtained directly from their owners after having discussed all treatment alternatives and the investigational status of Hpd/PRT. The animals were returned to their owners following treatment. Radiology was used to determine the size and extent of the mass, presence of metastasis and to aid in fiberoptic placement in tumors to be treated. All lesions were confirmed by biopsy and histopathology.<sup>10,21</sup> Other tests such as electrocardiograms, urinalyses, and microbial cultures were performed if deemed necessary.<sup>10,21</sup>

The Hpd used was Photofrin-V<sup>a</sup>, which is produced by dissolving hematoporphyrin in glacial acetic acid and sulphuric acid. The solution was filtered and neutralization with sodium acetate formed a precipitate. The precipitate was washed and stored at  $-20^{\circ}\text{C}$  until needed. For injection, one part Hpd was mixed with sodium hydroxide, neutralized with hydrochloric acid, and diluted with sodium chloride to a final concentration of 5mg/ml. Millipore filtration rendered the solution sterile.<sup>1</sup>

Two to three days prior to light treatment, 3.0 to 5.0 mg/kg Hpd was injected intravenously. This allowed adequate drug concentration in the tumor and clearance by normal tissues. During this time the animals were kept out of sunlight or bright light to minimize photosensitivity reactions. Photosensitivity appears as a transient sunburn/edema/erythema reaction that is reversible with antihistamines. Minimal problems have been observed in animals due to their pigmentation and hair coat.

<sup>a</sup>Oncology Research and Development, Inc., Cheektowaga, NY.

At the time of light treatment the animals were anesthetized with thiamylal sodium and halothane, or xylazine and ketamine. The area of the tumor was clipped and prepped for surgery. The treatment light source was produced by an argon ion laser. This produced enough light energy to pump a Rhodamine B dye laser operating without the tuning element. A broad output spectrum between 625 and 640 nm resulted which was then narrowed to  $630 \pm 2$  nm with a birefringent filter. The beam was split into four beams and coupled with fiberoptics. Coupling efficiency was greater than 70% within the fiber lengths used. The ends of the fibers were cut optically flat after stripping back 1–2 cm of the protective teflon coating.

If the mass was less than 1.0–1.5cm in diameter, four 18-gauge needles were inserted in the tumor in a tetrahedral pattern with 1cm sides. The optical fibers, having been cold sterilized and cleaned with 70% ethanol, were inserted through the needles to a distance 1mm beyond the needle tips. If excessive bleeding occurred through the needle, the needle and fiber were withdrawn and reinserted a short distance away. This was necessary since hemoglobin absorbs light slightly at 630nm.

If the tumor was greater than 2cm in diameter, the fibers were implanted in several areas sequentially to ensure light delivery throughout the mass and the most adjacent normal tissue. Treatment times ranged from 15–30 minutes at 120–900 milliwatts/fiber but was determined to be optimal at 20 minutes at 250mW/fiber. This delivered 300 Joules/fiber/insertion. Total time for a treatment session was usually 2 hours. With large tumors surgical debulking was performed one week prior to phototherapy to lessen treatment time and decrease the amount of necrotic tissue. During treatment, power was increased slowly and the light emanating from the tumor was observed to ensure proper light levels and adequate fiber positioning.

As PRT proceeded, the tumor increased in size due to edema and cell necrosis; some tumors also appeared dark or discolored due to necrosis. The edema usually regressed in 48 hours. Tissue response ranged from fluid drainage to severe frank necrosis and sloughing. Granulation and healing occurred at a normal rate, and by three weeks, determination of tumor regrowth was possible. There are no contraindications to repeated treatments as long as it is safe for the animal to

again be anesthetized. Large tumors that could not be surgically reduced prior to PRT were retreated at close intervals; with such a treatment schedule the dose of Hpd should be decreased by one-third or one-half if given within four to six days of the previous injection.

Post-treatment care was similar to that for any surgical procedure. Doxorubicin HCl (Adriamycin®) is the only known drug to be contraindicated. Antibiotics, steroids, fluids, cleansing of the sloughing tissue, diuretics, and other compounds all were used as needed. The patients were rechecked weekly for at least one month and then monthly if all seemed to be progressing well. Chemotherapy other than doxorubicin may be used in an effort to control micrometastasis.<sup>5,6,21</sup>

The results of PRT on pets have been very encouraging for certain types of solid malignant tumors. Table 1 gives the results of PRT in 75 animals with 25 histological tumor types. Seventeen have been in remission for over a year and 44 (59%) are in complete remission. Partial response was seen in an additional 23 cases. Those tumors unresponsive to the therapy were in the long bones of the extremities (two osteosarcomas, one myxoma, and one fibrosarcoma). Three animals were lost to follow-up. The longest follow-up is of a cat treated for osteogenic sarcoma of the mandible six years ago.

Favorable response was seen with osteosarcoma of the head, malignant melanoma, fibrosarcoma, malignant mast cell sarcoma, adamantinoma and synovial cell carcinoma. Both favorable and unfavorable responses were seen with squamous cell carcinoma, adenocarcinoma, leiomyosarcoma, and hemangiopericytoma. The differences in response have not been explained but are similar to those being seen in human medicine. Many variables can affect the response of the tumor to therapy. Alteration of the circulation to the tumor may change the amount of Hpd being delivered to the mass. Passage of the drug into the tumor cells and surrounding tissue are dependent on the permeability of the tumor vessels. Tissue density (e.g. bone or melanin granules) can alter the penetrating ability of light. Less understood variables, such as the fact that osteogenic sarcoma of the head is more osteoblastic while osteogenic sarcoma of the limbs is more lytic, also may play a part.<sup>5,6</sup>

### Summary

Phototherapy looks to be a very promising

new development in the field of oncology and the treatment of discrete solid tissue tumors. It is showing itself to be very effective and reliable for several histopathologic types of tumors which do not respond well to presently available modalities. One such tumor is the osteogenic sarcoma of the head. Not only has photoradiation therapy eradicated some tumors, but it does so without damage to adjacent healthy tissue. This allows the healthy tissues to fill-in the defect and remodel the bone. Good results (complete remission) were also seen with mammary adenocarcinomas in the cat. This highly malignant neoplasia previously carried a poor prognosis even with surgery.

The ability to deliver light directly to the tumor via fiber optics extends the use of PRT to any site reached by needles or an endoscope. Previously, chemotherapy or surgery were the main alternatives for neoplasia of the lungs, throat, bladder, vagina, and colon. PRT may be a safer, less-invasive alternative.

The technique is a simple one, making it a good procedure for the practitioner. The cost of the equipment is prohibitive at the current time, but it has been proposed that a metropolitan area with a population of greater than 750,000 could produce enough cases to justify a regional unit.<sup>9</sup> Furthermore, as lower cost light sources are developed, PRT could be put into even more widespread use.

Problems remain to be further investigated. More work is needed to determine exactly why some types of neoplasia do not respond to treatment. The recurrence of new squamous cell lesions adjacent to the site of previous treatment points to the need to develop better ways to initially evaluate the extent of the lesions. It would be helpful to be able to assay for Hpd levels to predict response to treatment and plan further therapy; currently no such assay is available.<sup>21</sup> Lastly, large tumors require long and/or repeated periods of anesthesia which may not be well tolerated by some patients; a larger dose of Hpd to increase the effective treatment volume and the coupling of multiple fibers to the laser are being investigated.<sup>21</sup>

As with any tumor treatment protocol, PRT has its advantages and disadvantages. Its adaptability, however, allows it to be effectively used as a primary treatment or as an adjuvant to surgery or as an alternative to radiation and chemotherapy. With time and further study and development, its benefits are increasing

and its limitations are decreasing. The clinical simplicity and apparent safety of this therapy makes it possible that PRT may soon take a place alongside the more conventional tumor therapies.

### References

1. Forbes IJ, Cowled PA, Leong AS-Y, Ward AD, Bleack RB, Blake AJ, Jacka FJ: Phototherapy of human tumors using haematoporphyrin derivative. *Med J Aust* 2:489-493, 1980.
2. Doiron DR, Profio E, Vincent RC, Dougherty TJ: Fluorescence bronchoscopy for detection of lung cancer. *Chest* 76:27-32, 1979.
3. Lipson RL, Baldes EJ, Olsen AM: The use of a derivative of hematoporphyrin in tumor detection. *J Natl Cancer Inst* 26:1-8, 1961.
4. Kelly JF, Snell ME: Hematoporphyrin derivative: A possible aid in the diagnosis and therapy of carcinoma of the bladder. *J Urol* 115:150-151, 1976.
5. Gomer CJ, Dougherty TJ: Determination of (<sup>3</sup>H)- and (<sup>14</sup>C)-hematoporphyrin derivative distribution in malignant and normal tissues. *Can Res* 39:146-151, 1979.
6. Kessel D, Chou T-H: Tumor-localizing components of the porphyrin preparation hematoporphyrin derivative. *Can Res* 43:1994-1999, 1983.
7. Dougherty TJ, Gomer CJ, Weishaupt KR: Energetics and efficiency of photoinactivation of murine tumor cells containing hematoporphyrin. *Can Res* 36:2330-2333, 1976.
8. Weishaupt KR, Gomer CJ, Dougherty TJ: Identification of singlet oxygen as the cytotoxic agent in photoinactivation of a murine tumor. *Can Res* 36:2326-2329, 1976.
9. Thoma RE: Phototherapy, in Kirk R (ed): *Current Veterinary Therapy VIII*. Philadelphia, W.B. Saunders Co., pp 438-441, 1983.
10. Thoma RE, Stein RM, Wishaupt KR, Dougherty TJ: Phototherapy: a promising cancer therapy. *VM/SAC* 78:1693-1699, 1983.
11. Cortese DA, Kinsey JH: Hematoporphyrin derivative phototherapy for local treatment of cancer of the tracheobronchial tree. *Ann Otol Rhinol Laryngol* 91:652-655, 1982.
12. Dahlman A, Wile AG, Burns RG, Mason GR, Johnson FM, Berns MW: Laser photoradiation therapy of cancer. *Can Res* 43:430-434, 1983.
13. Wile AG, Dahlman A, Burns RG, Berns MW: Laser photoradiation therapy of cancer following hematoporphyrin sensitization. *Laser in Surgery and Medicine* 2:163-168, 1982.
14. Soma H, Akiya K, Nutahara S, Kato H, Hayata Y: Treatment of vaginal carcinoma with laser photoradiation following administration of hematoporphyrin derivative. *Annales Chirurgiae et Gynaecologiae* 71:133-136, 1982.
15. Gomer CJ, Doiron DR, Jester JV, Szirth BC, Murphree AL: Hematoporphyrin derivative photoradiation therapy for the treatment of intraocular tumors: examination of acute normal ocular tissue toxicity. *Can Res* 43:721-727, 1983.
16. Laws ER, Cortese DA, Kinsey JH, Eagan RT, Anderson RE: Photoradiation therapy in the treatment of malignant brain tumors: a phase I (feasibility) study. *Neurosurgery* 9:672-678, 1981.
17. Cortese DA: Hematoporphyrin derivative in the detection and localization of radiographically occult lung cancer. *Am Rev Respir Dis* 126:1087-1088, 1982.
18. Hayata Y, Kato H, Konaka C, Ono J, Matsushima Y, Yoneyama K, Nishimiya K. Fiberoptic bronchoscopic laser photoradiation for tumor localization in lung cancer. *Chest* 82:10-14, 1982.
19. Cortese DA, Kinsey JH: Endoscopic management of lung cancer with hematoporphyrin derivative phototherapy. *Mayo Clin Proc* 57:543-547, 1982.
20. Benson RC, Farrow GM, Kinsey JH, Cortese DA, Zincke H, Utz DC: Detection and localization of in situ carcinoma of the bladder with hematoporphyrin derivative. *Mayo Clin Proc* 57:548-555, 1982.
21. Dougherty TJ, Thoma RE, Boyle DG, Weishaupt KR: Interstitial photoradiation therapy for primary solid tumors in pet cats and dogs. *Can Res* 41:401-404, 1981.



## OTS Seminar

Omega Tau Sigma will host a practitioner's seminar on October 27, 1984. Topics of the seminar will be *Computers and the Veterinarian*, and *New Aspects of Diagnosis and Treatment of Heart Disease*. For more information contact:

Omega Tau Sigma  
Practitioner's Seminar  
300 Wellons  
Ames, IA 50010