

1996

## Patent Ductus Arteriosus in Dogs

Heidi E. Houghton  
*Iowa State University*

Wendy A. Ware  
*Iowa State University*

Follow this and additional works at: [https://lib.dr.iastate.edu/iowastate\\_veterinarian](https://lib.dr.iastate.edu/iowastate_veterinarian)

 Part of the [Animal Diseases Commons](#), [Cardiovascular Diseases Commons](#), and the [Small or Companion Animal Medicine Commons](#)

---

### Recommended Citation

Houghton, Heidi E. and Ware, Wendy A. (1996) "Patent Ductus Arteriosus in Dogs," *Iowa State University Veterinarian*: Vol. 58 : Iss. 2 , Article 13.

Available at: [https://lib.dr.iastate.edu/iowastate\\_veterinarian/vol58/iss2/13](https://lib.dr.iastate.edu/iowastate_veterinarian/vol58/iss2/13)

This Article is brought to you for free and open access by the Journals at Iowa State University Digital Repository. It has been accepted for inclusion in Iowa State University Veterinarian by an authorized editor of Iowa State University Digital Repository. For more information, please contact [digirep@iastate.edu](mailto:digirep@iastate.edu).

# Patent Ductus Arteriosus in Dogs

Heidi E. Houghton, DVM \*  
Wendy A. Ware, DVM, MS, DACVIM \*\*

Patent ductus arteriosus (PDA) is the most common congenital cardiovascular defect in canines.<sup>1</sup> PDA represents a failure of the fetal ductus arteriosus to properly close after birth. PDA is usually recognized in young dogs, but is occasionally seen in middle aged to older animals. Four clinical presentations of PDA have been described and likely represent a continuum of severity. They are based on the size of the patency and the direction of the shunt. Many dogs are asymptomatic at the time of diagnosis. Approximately 50% of untreated cases will die of congestive heart failure within the first year of life.<sup>2</sup>

## Incidence

PDAs occur more frequently in female dogs (3:1 sex ratio) and in certain breeds.<sup>3</sup> The breeds most affected by PDA are: miniature and toy poodle, collie, Pomeranian, Shetland sheepdog, Maltese, English springer spaniel, Yorkshire terrier, German shepherd, and cocker spaniel.<sup>3,4,5,6</sup> Affected dogs should not be bred. Inheritance is thought to be polygenic. Phenotypically, normal dogs that are closely related to dogs with PDA may be carriers and also should not be bred.<sup>4</sup>

## Pathogenesis

Normal functional ductal closure occurs within hours after birth. Within a few days, massive changes in the ductal wall transform the structure into a fibrous cord, which is referred to as the ligamentum arteriosum.<sup>4</sup>

Failure of ductal closure results from his-

toxic abnormalities of the ductal wall. Normal ductal wall contains a loose branching pattern of circumferential smooth muscle. Dogs with PDA have a subnormal amount and asymmetric distribution of this ductus specific smooth muscle. A reciprocal increase in amounts of elastic tissues in areas that should be smooth muscle results in a ductal wall that is more like the aorta. These wall changes preclude the normal closure of the ductus.<sup>7</sup>

## Pathophysiology

**Left-to-Right Shunt** Since aortic pressure is normally greater than pulmonary artery pressure, blood continuously shunts from the aorta into the main pulmonary artery. This causes a continuous "machinery" cardiac murmur. Increased pulmonary blood flow and venous return to the left heart are the result. The volume overload causes left atrial and ventricular dilation, hypertrophy, and increased ventricular diastolic pressure. Left ventricular failure with pulmonary edema may develop from volume overload, especially with a large defect and relatively normal pulmonary vascular resistance. The left ventricular stroke volume is increased due to increased filling (Frank-Starling principle). Aortic diastolic pressure is low due to run-off of blood through the ductus. This widens the pulse pressure and results in a hyperkinetic or bounding pulse.<sup>8</sup>

**Right-to-Left Shunt** A small percentage of PDAs exhibit "reversed" flow, with blood shunting into the descending aorta from the pulmonary artery. These dogs have a very high pulmonary vascular resistance, which induces systemic pressures in the right ventricle and pulmonary artery. Decreased pulmonary flow, a small left ventricle and marked hypertrophy of the right

\* Dr. Houghton is a 1996 graduate of the Iowa State University College of Veterinary Medicine.

\*\* Dr. Ware is an associate professor at the Iowa State University College of Veterinary Medicine Department of Veterinary Clinical Sciences.

ventricle are seen along with evidence of caudal hypoxemia. The exact mechanism of the increased pulmonary vascular resistance is not completely understood.<sup>8</sup> In these cases shunt reversal is thought to occur at an early age. The ductal lumen in these dogs is anatomically very large.

### Clinical Description

**Type 1** (small PDA) is characterized by an asymptomatic left to right shunt with a high frequency continuous murmur heard only at the high left heart base. The heart rate and pulse quality are normal in these dogs and a precordial thrill is faint or not present at the left heart base. Radiographs and electrocardiography (ECG) are normal in these dogs, even at two years. Surgery is recommended, but not urgent.<sup>3</sup>

**Type 2** (medium PDA) is also characterized by an asymptomatic left to right shunt. However, PDA's in this category have a coarse, continuous murmur heard at the left heart base and left apex. The pulse is normal to slightly bounding, and mild to moderate left heart enlargement develops by one year of age. A small-to-medium sized ductus aneurysm may be present, and left ventricular enlargement is usually indicated on the ECG by R waves exceeding 3mV in lead II. Borderline increases in pulmonary vascular markings are present.<sup>3</sup>

**Type 3** (large PDA) is subdivided into those with (3a) and without (3b) congestive heart failure (CHF). Dogs with Type 3a usually have a reduced exercise capacity, a coarse continuous murmur and thrill over the left thorax, a systolic murmur of mitral regurgitation, bounding pulse due to wide pulse pressure, marked left heart enlargement by six months of age, a medium to large ductal aneurysm, a significant increase in pulmonary vascular markings and ECG lead II R waves possibly exceeding 5mV. Surgery is recommended immediately in these cases. Type 3b is characterized by the above signs plus those of CHF including dyspnea caused by pulmonary edema, cachexia, and possible atrial fibrillation or other arrhythmias. The

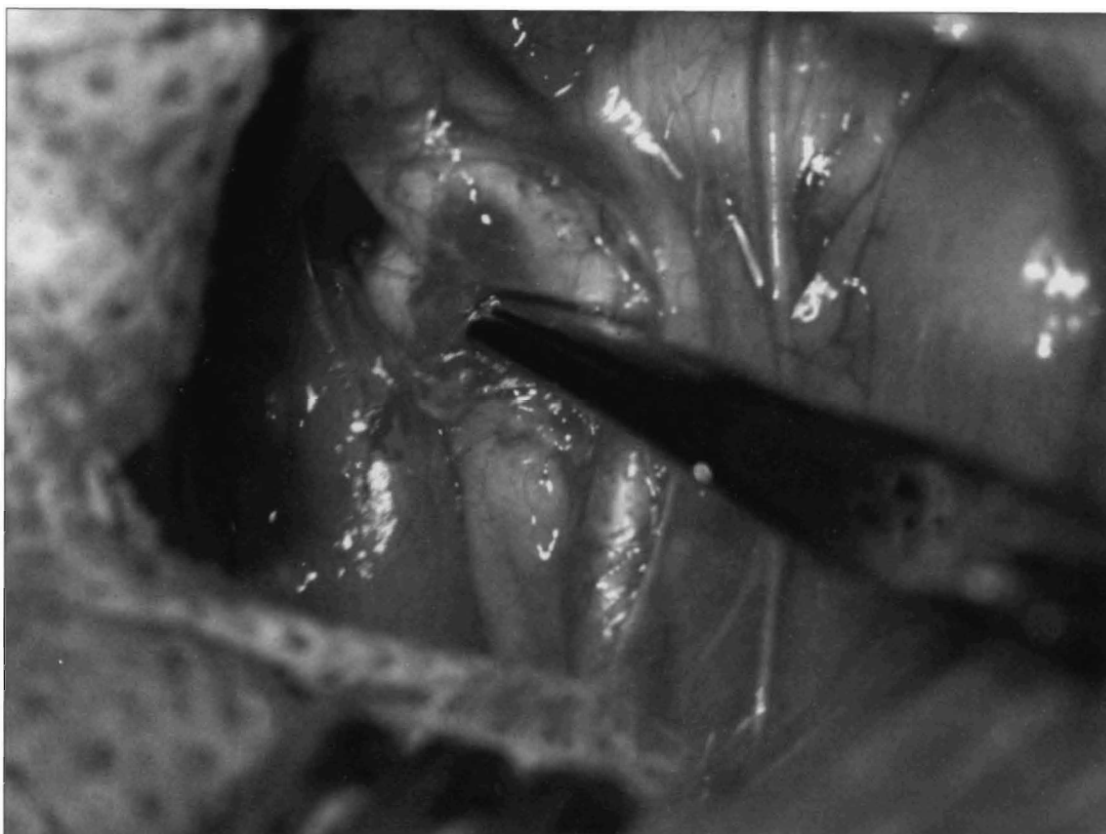
pulmonary edema must be resolved as much as possible before surgery is performed. This is accomplished by cage rest, furosemide, supplemental oxygen, an angiotensin converting enzyme inhibitor and digitalization.<sup>3</sup>

**Type 4** (large PDA) is associated with pulmonary hypertension. This type is either a right-to-left or equally balanced shunt and is found in dogs from 2 weeks to 12 years. Prognosis and longevity are poor in dogs with pulmonary pressures high enough to cause right to left shunting. Hindleg weakness or collapse with exercise may be present. Differential cyanosis (caudal, but not oral membranes) may be present and pulses are normal to weak. Usually a murmur or precordial thrill is not present, but a split and/or prominent second heart sound may be detectable. A right axis deviation on ECG, large right heart and main pulmonary artery with normal to decreased pulmonary vessels on radiographs, and polycythemia are also features of this type. Surgery is contraindicated in Type 4 PDAs, and medical management including periodic phlebotomy is indicated.<sup>3</sup>

An incomplete ductal closure occurs in some dogs. This is the non-patent forme fruste (or ductus diverticulum)<sup>3,4</sup>, where the ductus is completely closed at one point (usually the pulmonary arterial end), but the remainder of the ductus stays open. There is no murmur nor any other clinical sign associated; diagnosis is made (usually incidentally) by angiography.

### Diagnosis

The physical examination and history provide clues in the diagnosis and classification of a PDA. Knowing what breeds are predisposed to certain defects may suggest a problem, but assessing mucous membrane color, pulse character, capillary refill time, presence or absence of a precordial thrill, and heart sounds are the most important part of the initial work up and suggest the differential diagnosis.<sup>5</sup> It is important to assess both the cranial (oral) and caudal (vaginal or preputial) mucous membranes when exam-



Mary A. Nieves, DVM

**Visualization and isolation of patent ductus arteriosus.**

ining a dog with a suspected cardiovascular defect, because a reversed or right-to-left shunting PDA can result in a differential cyanosis. This occurs because the ductus arteriosus is distal to the arteries supplying the head and therefore the cranial mucous membranes appear normal. Dark red mucous membranes suggest polycythemia which may be in response to chronic hypoxia as is seen in dogs with large right to left shunts. Decreased capillary refill time indicates a decrease in the regional blood flow and could signal low cardiac output and heart failure.<sup>5</sup>

Chest palpation should be done to check for caudal displacement of the cardiac impulse which suggests cardiomegaly and also to check for a precordial thrill. The arterial pulse character is most easily assessed on the femoral artery. A bounding or "water hammer" pulse suggests a PDA and is due to a widened pulse pressure.<sup>5</sup> Signs of right heart failure such as jugular venous disten-

tion, hepatosplenomegaly and ascites are not expected with defect.<sup>5</sup>

Thoracic auscultation should include evaluation of all four valvular areas and determining the point of maximal intensity (PMI) of the murmur. The PMI for a PDA is the high left heart base. If an apical systolic murmur is heard, evaluation of the heart base for a diastolic component is warranted as these are features of a PDA. Murmurs should be characterized by grade I through VI, timing (left to right shunting PDA's have a continuous murmur), and radiation of the murmur. Finally, the acoustic quality of the murmur should be assessed. PDAs produce a continuous murmur of a machinery like quality which is loudest during systole.<sup>5</sup>

**Thoracic radiographs** taken routinely may reveal cardiomegaly, left atrial and auricular (atrial appendage) enlargement, enlarged pulmonary vessels, aneurysmal dilation of the proximal descending aorta and possibly signs of left heart failure such as

pulmonary venous distension or edema.<sup>6,9</sup>

**Electrocardiography** in dogs with PDA usually reveals wide P waves, deep Q waves in lead II and very tall R waves in the caudal leads.<sup>6</sup>

**Echocardiography** performed on dogs with PDA reveals dilation of the pulmonary trunk, left atrial and ventricular enlargement and sometimes the ductus itself, can be visualized. Doppler studies document continuous and turbulent flow into the pulmonary artery from the aorta.<sup>6</sup>

**Cardiac catheterization** is usually not necessary, but when performed normally reveals a higher oxygen content in the pulmonary artery than the right ventricle and a wide aortic pulse pressure.<sup>6</sup> Structural changes in the cardiac chambers and abnormal ductal flow are evident with angiography.

### **Treatment: Surgery**

Once a left-to-right PDA has been diagnosed, surgical ligation is recommended, as discussed earlier. Several surgical techniques are available for PDA surgery. Atropine may be given preoperatively because manipulation of the left recurrent laryngeal and vagus nerves may cause reflex slowing of the heart.<sup>3,10</sup> A left lateral thoracotomy is performed at the fourth or fifth intercostal space. Positive pressure ventilation is started when the thoracic cavity is exposed. The left cranial, and sometimes the middle, lung lobes are reflected caudally.<sup>3,10,11,12</sup> The ductus is now seen ventral to the aorta and dorsal to the pulmonary artery. Fremitus can be palpated ventral and anterior to the ductus where the blood flow from the shunt is reflected off the pulmonary artery near the pulmonary valve.<sup>10</sup>

At this point, various options are available to the surgeon. The recurrent laryngeal and vagal nerves are reflected back with a suture placed in a pleural flap or directly with umbilical tape.<sup>10,11</sup> The use of gas-sterilized swabs to dissect the ductus has been suggested as being safer and more expedient than traditional methods.<sup>11</sup> Others advocate

the use of right-angled forceps to reach the ductus.<sup>10,12</sup> Once the ductus is dissected, it can be ligated with a variety of suture materials and a variety of methods of suture placement.<sup>3,10,11,12</sup> The use of tantalum hemostatic clips for occlusion of a patent ductus was first introduced in 1971.<sup>13</sup> While some believe ducts closed in this way recanalize, no published evidence of recanalization was found by the authors.

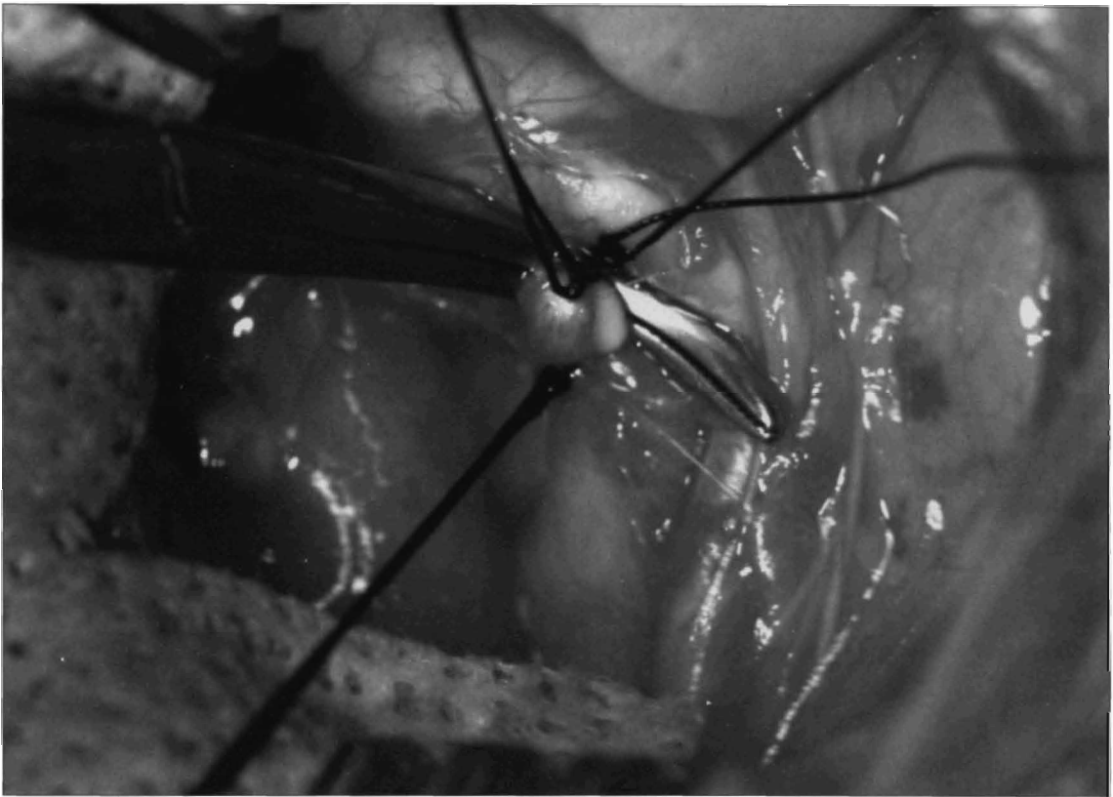Another method is division of the ductus between clamps. This is usually reserved for large PDAs and involves placing patent ductus clamps adjacent to the aorta and pulmonary trunk, transecting the ductus, and closing first the pulmonary artery side and then the aortic side in a continuous over-and-over pattern with silk suture.<sup>3</sup>

After the ductus has been occluded, the pericardial edges are apposed to prevent herniation of the left auricle and a chest tube is placed several rib spaces posterior to the thoracotomy. Rib sutures are then placed, the ribs are drawn together and the sutures are tied. The muscle layers and skin are then closed.<sup>10</sup> Negative pressure is placed on the chest tube when the thoracic cavity is no longer open. The chest tube may be removed immediately or whenever it is no longer needed.<sup>10,11</sup>

Complications of PDA surgery include hemorrhage, congestive heart failure, endocarditis, thromboembolism, recanalization, rupture of the ductal aneurysm, and arrhythmia.<sup>3</sup> Postoperative care consists of hospitalizing the dogs for 2 days to 3 days and standard monitoring. A systolic murmur of mitral regurgitation caused by annular dilation may be noticed, but should disappear rapidly.<sup>3</sup> Exercise should be restricted for one month and digoxin, if the dog was on it pre-operatively, should be continued until a recheck examination is performed in 2 months. Most dogs live a normal life span if the PDA is surgically corrected before the onset of congestive heart failure.<sup>3</sup>

### **Medical Management**

Medical management is indicated for re-



Mary A. Nieves, DVM

**Ligation of patent ductus arteriosus.**

versed PDA's with secondary polycythemia. Treatment includes enforced rest, exercise limitation, stress avoidance, and maintenance of packed cell volume (PCV) between 62% to 68%. Fluid volume should be maintained during phlebotomy with crystalloid solutions.<sup>8</sup> V

**References**

1. Buchanan JW. Causes and prevalence of cardiovascular diseases. In: Kirk RW, Bonagura JD, eds. *Current Veterinary Therapy XI*. Pennsylvania: W.B. Saunders Company; 1992:647-655.
2. Johnston SA, Eyster GE. Patent Ductus Arteriosus. In: Kirk RW, Bonagura JD, eds. *Kirk's Current Veterinary Therapy XII*. Pennsylvania: W. B. Saunders Company; 1995:830-833.
3. Buchanan JW. Patent Ductus Arteriosus. *Seminars in Veterinary Medicine and Surgery*. 1994;9:168-176.
4. Patterson DF. Hereditary congenital heart defects in dogs. *Journal of Small Animal Practice*. 1989;30:153-165.
5. Goodwin JK, Lombard CW. Identifying congenital heart defects using clues from the physical exam. *Veterinary Medicine*. 1990:40-47.
6. Ware WA. Disorders of the Cardiovascular System. In: Nelson RW, Couto CG, eds. *Essentials of Small Animal Internal Medicine*. Missouri: Mosby-Yearbook; 1992:115-116.
7. Buchanan JW. Morphology of the ductus arteriosus in fetal and neonatal dogs genetically predisposed to patent ductus arteriosus. *Birth Defects*. 1978;14:349-360
8. Bonagura JD, Drake PGG. Congenital Heart Disease. In: Ettinger SG, Feldman EC, eds. *Textbook of Internal Medicine*. 4th ed. Vol. 1. Pennsylvania: W.B. Saunders Company; 1995:892-943.
9. Goodwin JK, Lombard CW. Patent Ductus Arteriosus in Adult Dogs: Clinical Features of 14 Cases. *Journal of the American Animal Hospital Association* 1992;28:349-354.
10. Eyster, GE. Basic Cardiac Surgical Procedures. In: Slatter DH, ed. *Textbook of Small Animal Surgery*. 2nd ed. Pennsylvania: W.B. Saunders Company; 1985;1:897-900.
11. Wolfe DA. Patent Ductus Arteriosus in Dogs: A Surgical Review and Simplified Technique. *Journal of the American Animal Hospital Association*. 1979;15;3:323-328.
12. Jackson WF, Henderson RA. Ligature Placement in Closure of Patent Ductus Arteriosus. *Journal of the American Animal Hospital Association*. 1979;14:55-58.
13. Breznock EM, Hilwig RW. A Surgical Method for Correction of Patent Ductus Arteriosus in the Dog. *Journal of the American Veterinary Medical Association* 1971;158:753-762.